

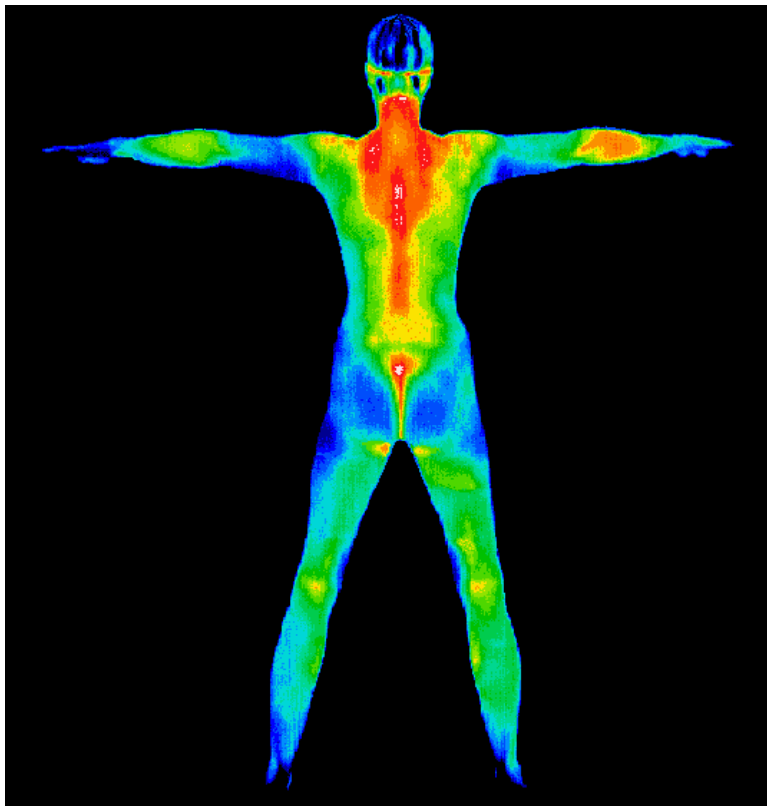
Digital Infra-Red Thermal Imaging (*DITI*)

For Referring Health Practitioners

Like all medical imaging methods, DITI is useful only within certain applicable conditions.

This introductory handbook is to help all practitioners gain a better understanding of which patients would benefit from this test and how to integrate the findings into clinical evaluation, diagnosis, monitoring treatment and decision making.

DITI is simply a non-invasive screening technology offering clinically significant information without side effects.



In today's medico-legal environment practitioner's are under ever increasing pressure to justify all invasive procedures.

DITI is a non-invasive imaging technique which can add case justification to subsequent investigations or procedures.

Introduction

Thermology - is the study of human thermal physiology.

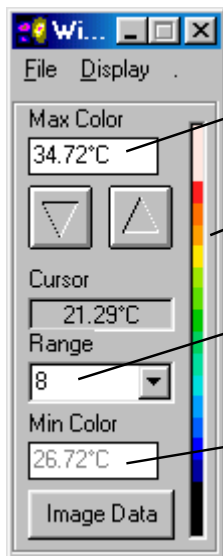
Thermography or Digital Infrared Thermal Imaging (DITI) is a non-invasive, diagnostic imaging procedure involving the detection and recording of a patient's cutaneous thermal patterns using instruments which can provide visual and quantitative documentation of these temperature measurements.

Thermography is appropriate and germane to any health care practice whenever the treating physician feels a *physiological* imaging test would help in a diagnosis or case management.

DITI only quantifies dermal infrared radiation (to a depth of 5.0mm +/-15%). DITI can not directly image deep structures or phenomena. However many pathophysiological states trigger thermal alterations in this 5mm of dermis via the micro-dermal circulatory beds, either intrinsically through localised phenomena, or extrinsically via effusion, vascular, neurological and/or neurovascular pathways. When used appropriately, DITI can contribute objective clinically significant data to a practitioner, allowing a greater level of confidence in diagnosis and a higher level of justification when ordering more invasive tests and procedures.

Thermal imaging has come a long way in the last twenty years, with a high level of refinement since the early 1990's. The advances in sensitivity and reliability (of both mechanism and resultant data) are due to the huge technological advances in computing, solid state miniaturisation and declassification of military electronic super cooling and infrared technology. Today's DITI scanners have super-cooled thermally stable receiver units capable of readings accurate to 100th of a degree.

In examining a DITI image, you will often see an information box like this one.



Max Color indicates the colour that represents the highest graded temperature, which in this case is White at 34.72°C

The colour bar indicated the range of colours used in this particular image, in this case 16 colours between white and black .

Range shows the spread of temperature represented by the colours. In this case it is 8°C which is the standard default.

Min Color indicates the colour that represents the lowest graded temperature, which in this case is black at 26.72°C

There are many varying colour maps used in DITI images. By having this colour bar and max. and min. information, a practitioner can know exactly what the displayed colours represent.

As alluded to above, the default format is in a range of eight degrees, with each grade of colour representing a half degree step, running from red to blue (colour map 3). Of course, to have any clinical significance, contra-lateral studies are always in the same scale and range.

If there is no colour bar information with an image, you may safely assume that it is set in the above default, excepting the actual temperature of the scale, which is adjusted to give the best image and thermal patterns for an image.

For practitioners interested in referring patients, a copy of the image manipulation software is available, and the patient's relevant images can be emailed or copied to disk and sent to the practitioner for his or her own interest.

READING THE IMAGE

It is easy to be distracted by colour, especially the higher frequencies. The main thing that DITI shows is thermal asymmetry in contra-lateral comparison, areas of unusual hypo or hyperthermia, and combined patterns. In the following case studies, you will see how the patterns indicate very different conditions.

Essentially, the pathophysiological phenomena suitable for a DITI screening investigation can be divided into three broad categories:

1. Inflammatory phenomena
 - a. Infections – post surgical and common
 - b. Musculo-skeletal dysfunction
 - c. Periosteal irritations
 - d. Myofascial trigger points
 - e. Active arthritis
 - f. Soft tissue injury/sports injury
2. Vasomotive phenomena
 - a. Radicular neuropathies
 - b. Reflex sympathetic dystrophy
 - c. Neuropathological referrals
3. Vascular phenomena
 - a. Angiogenesis (particularly perineoplastic growth)
 - b. Varices (thrombophlebitis & DVT)
 - c. Ischaemic phenomena

Inflammatory Phenomena

Post-Surgical Infections

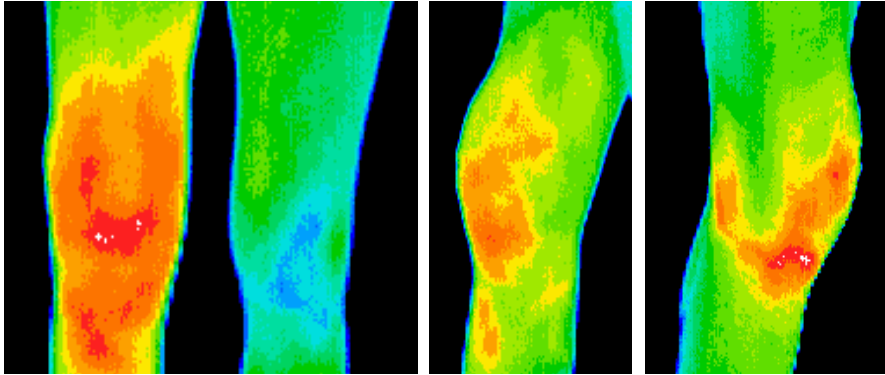
Post surgical assessments are hampered by a number of factors, not the least of which is the level of subjective reporting required by a patient. Varying patient expectations and experiences are confounding factors in post surgical infection assessments.

DITI allows visualisation of Thermogenic phenomena both directly, and via effusion. This is limited to soft tissue and joints, with fully contained osteomyelitis demonstrating DITI findings which are equivocal at best.

Anterior Knees

Medial Right knee

Lateral Right knee



Right knee surgery was followed with a painful effusion in the early post operative period.... Thermography confirmed a significant inflammatory reaction. 30cc of blood-stained fluid was aspirated.. Thermography can quantify all grades of joint synovitis and is able to demonstrate minimal changes due to NSAID's

Thermogenic Infections

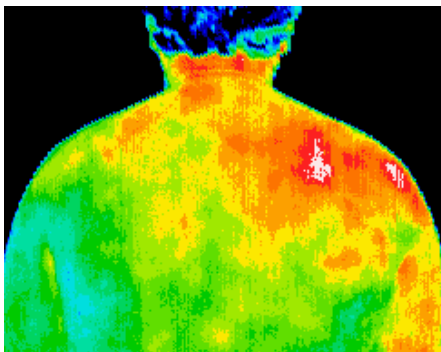
In cases of thermogenic infections (i.e. pyogenic infections), it is unlikely that DITI would be used in the diagnostic phase, as case history and physical inspection is normally sufficient to initiate a treatment protocol until pathology reports can return. DITI is particularly useful in quantifying the efficacy of a treatment protocol. In cases of depressed immune response or other at risk categories, where a practitioner is concerned with a protocol's efficacy, the effusion boundaries can be clearly quantified and measured in a DITI scan.

By progressive monitoring of an infection site, the regression and resolution of an active infection can be non-invasively monitored.

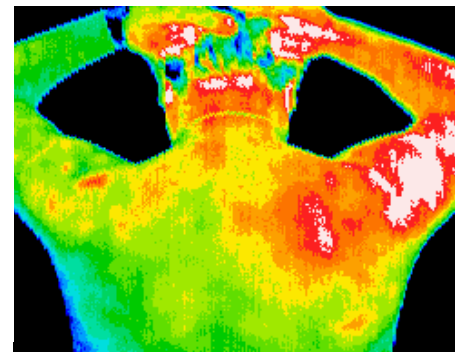
Musculo-Skeletal Dysfunction

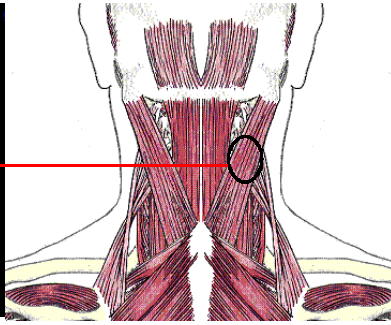
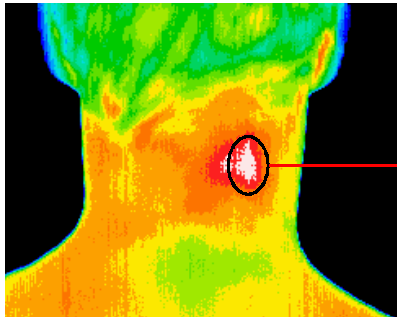
Possibly one of the more confounding patient complaints is that of musculo-skeletal dysfunction. Patient subjectivity in reporting, malingering and overlaying symptoms are just some of the confounding factors in diagnosing this group of problems.

Most musculo-skeletal problems will result in inflammation of the local tissues primarily, and surrounding tissues to a lesser extent. These conditions make excellent studies in DITI terms. Because of vascular differentials in the various soft tissues, damage to muscle, tendon, ligament and periosteum all have quite distinct thermal signatures.



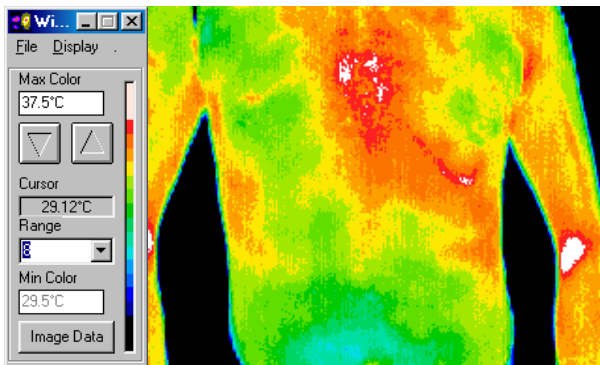
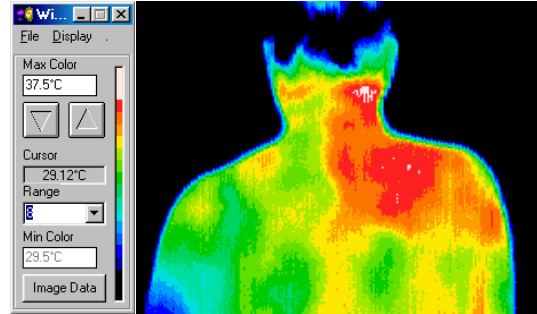
Significant inflammation throughout the right deltoid region. Thermographic findings indicated muscular rather than joint pathology





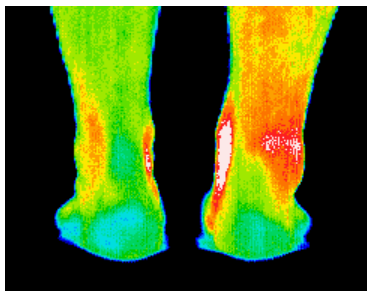
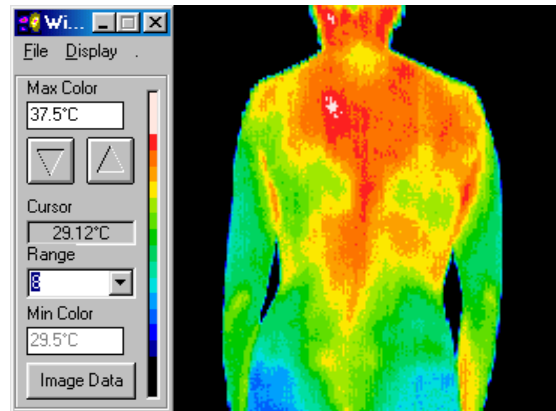
Well defined focal area of inflammation over the splenius capitis / splenius cervicis. Patients headache resolved after local IM anesthesia.

This patient with a torticollis was seen to have significant inflammation in the posterior neck and shoulder consistent with muscle spasm. There were no significant thermal asymmetries seen relating to the accessory nerve or the glands in the neck.

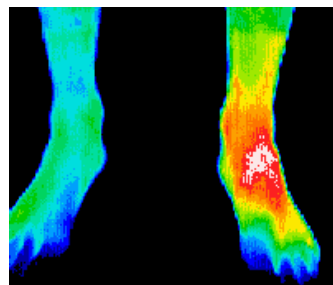


MVA patient with language difficulties, hospitalized, examined and discharged, presented two days later with chest pain. Thermology findings were sent with patient to radiology. Three fractures found in distal sternum plus small fracture in left rib.

Patient with scoliosis suffering from tension headaches. Inflammation seen over the left rhomboids was treated with remedial massage which gave relief.



Right ankle sprain with effusion



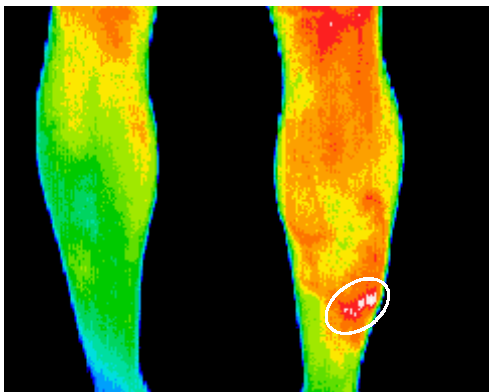
Left ankle sprain, tarsal region.

Periosteal Irritation

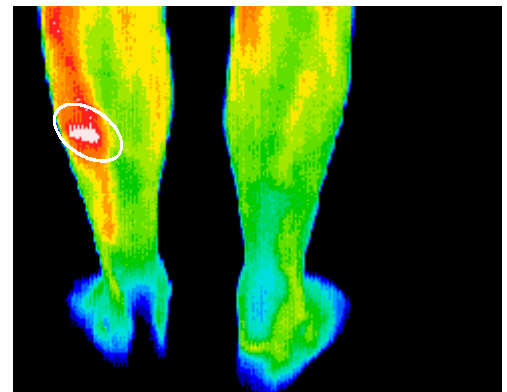
Stress fractures and periosteal micro-avulsion are perplexing problems for many practitioners concerned with radiation exposure levels of their patients. The most conclusive form of imaging for this type of injury is radio-isotope scanning (scintigraphy), which carries well documented radiation hazards.

DITI has a very high negative prediction rate with regard to stress fractures. By quantifying the presence or absence of periosteal irritation, which has a clear thermal signature, a positive DITI scan can justify a practitioner's ordering of a more invasive test. A number of practitioners who are satisfied with DITI's efficacy have begun to use just historical markers, and the DITI scans to form a diagnosis and recommend a treatment protocol.

DITI is especially useful in early cases where plain radiography often demonstrates equivocal or false negative findings, or in young patients undergoing puberty, where radiation should be kept as low as practicable.



Stress fractures - not identified on Xray but confirmed with Scintigraphy after localisation with thermography

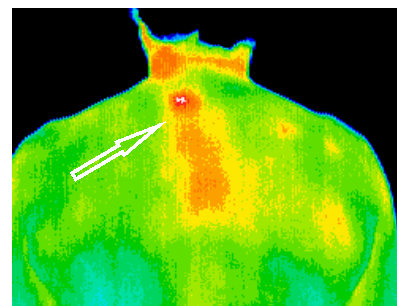
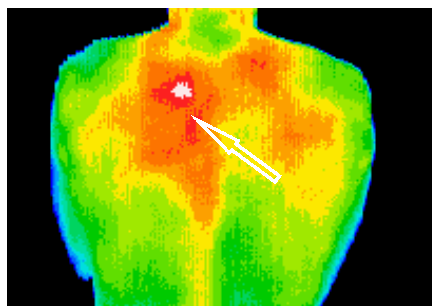
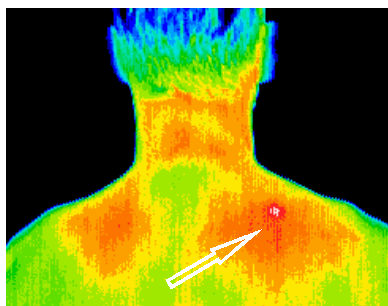


Myofascial Trigger Points

True trigger points which are active have a thermal signature that is rarely seen in any other phenomena, and is easily distinguished by historical markers. A patient complaining of a pain pattern which is following a known myofascial referral zone is a prime candidate for DITI investigation.

Once a trigger point is located and quantified, the practitioner can address the problem via their preferred protocols.

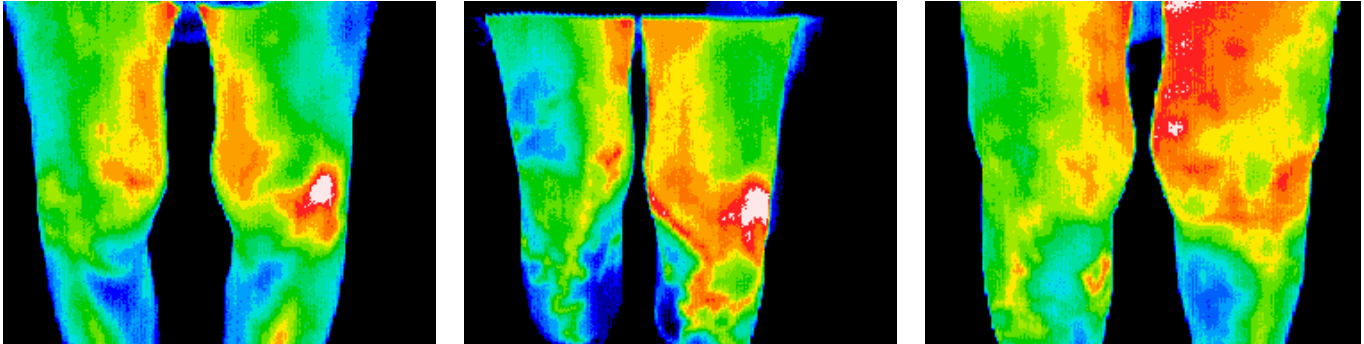
Interestingly, when a trigger point is seen, it is common to also see a diffuse hyperthermic pattern marking the referral zone, reinforcing the correct identification of a problem.



Active Arthritis

Arthritic conditions, once quantified by conventional means, can often mask other complaints. The challenge for the practitioner is one of determining whether the patient's subjective reports are likely to be of the arthritis, or another problem in the same zone.

Active arthritis shown clearly in a DITI scan as a distinct focal area of inflammation. If there is a complaint overlying an arthritic zone, DITI has a good chance of differentiating localised joint pain, sympathetic irritation (described later in the text) and other, more wide spread inflammation indicative of a separate infection or condition.



Soft Tissue Injury & Sports Injuries

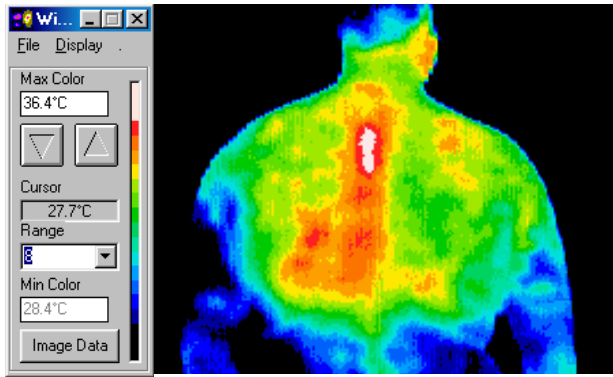
Soft tissues of the musculo-skeletal system (muscle, tendon, ligament and periosteum) have very different characteristics of vascularisation and innervation. These properties allow DITI to quantify the type of tissue injured with a high level of reliability.

Damage to highly vascular tissues like muscles will typically return a DITI scan demonstrating a focal area of irritation accompanied by a large effusive area primarily proximal to the injury site. Intramuscular haematoma will demonstrate as a combined involvement in the muscle belly and associated tendinous sheath. Extra-muscular haematoma generally exhibit enough physical signs that little doubt exists as to the nature of the injury and a DITI scan will be of little value.

Tendons, being relatively avascular and aneural exhibit very different DITI signs to muscular damage. Tendinous injury will exhibit comparatively little DITI focal area, and typically a diffuse hyperthermic response, with a proximal bias.

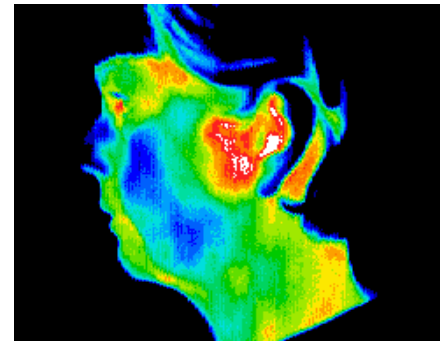
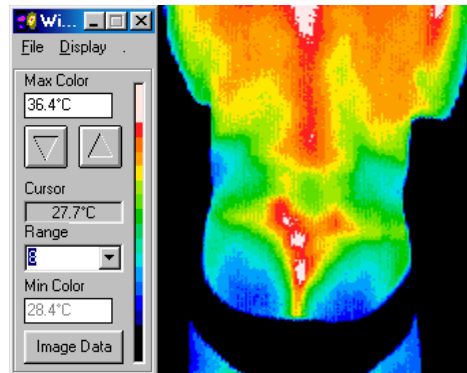Ligamentous injury exhibits a similar pattern to periosteal irritation. Ligament lesions tend to have a very localised inflammatory response, an immediate distal radicular neuropathic hypothermia pattern, and a proximal striated hyperthermic pattern.

Traumatic vascular injury is more effectively imaged by doppler ultrasound, and as such is typically outside of DITI's expected examination frame.

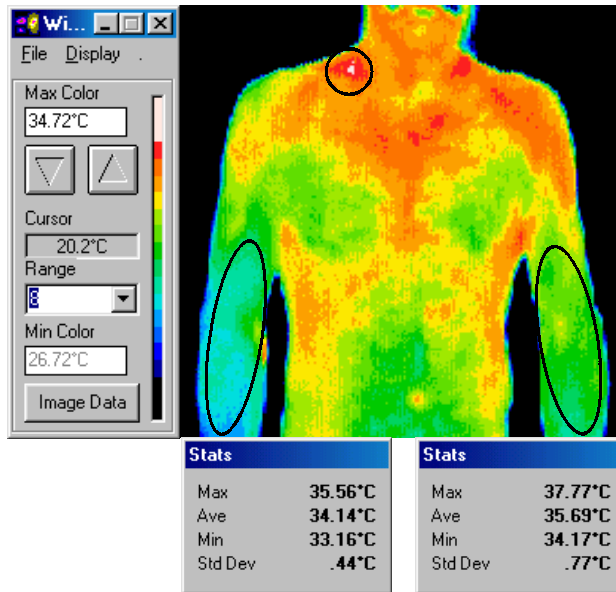


Weight lifter with a diagnosed T4 syndrome. Thermography increased the confidence in the diagnosis and established a baseline for comparative studies monitoring response to treatment.


Competitive Swimmer with pain in left gluteus maximus (swimmers nemesis)



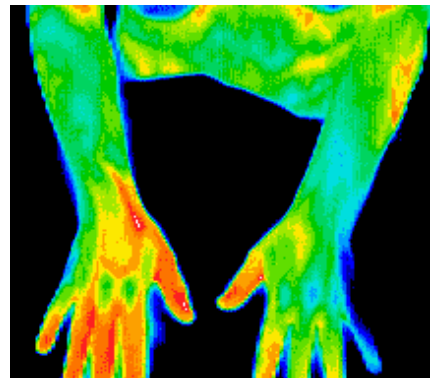
TMJ syndrome, thermography confirming diagnosis.



Right arm thrower with right arm weakness and paresthesia. Thermography showed an area of increased motor tone (sympathetic activity) in lower right arm with significant temperature differentials (hypothermia). There is also a local area of hyperthermia over the right brachial plexus. Patient was treated for brachial plexus entrapment and lower arm symptoms resolved.



Post fracture, poor healing response left ankle after cast removal, being monitored by thermography to help in decision making



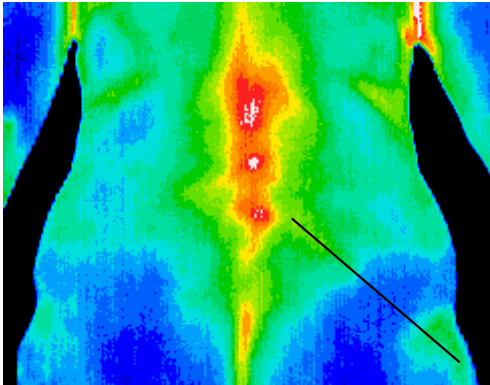
Golfer with left elbow pain that radiates distally through the ulna into the little finger. Thermography correlated well with the patients perception of pain when other tests were negative

Vasomotive Phenomena

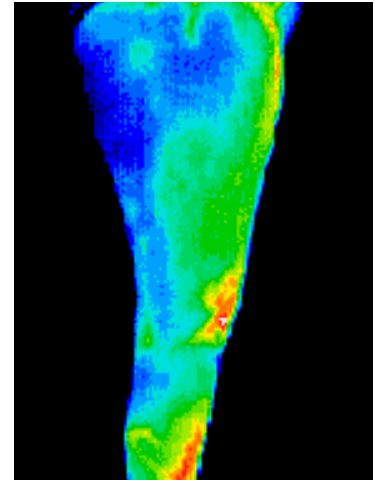
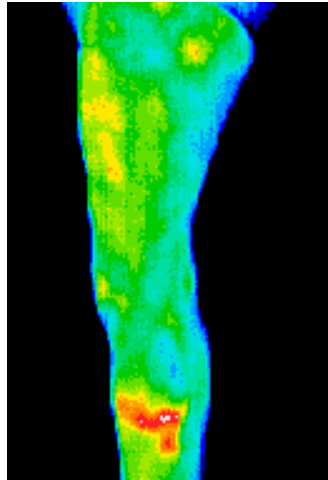
Radicular Neuropathies

Radicular neuropathies are clearly visualised by DITI scanning as an area of distinct unilateral hypothermia following a discrete sympathetic vaso-constrictive nerve supply area.

Symptoms of a radicular neuropathy may include posture dependent or independent neuralgia, anaesthesia, dysaesthesia, paraesthesia, and stiffness. As these symptoms also cover a multitude of other aetiologies, a DITI scan is a simple, non-invasive and objective modality to quantify radicular sympathetic involvement.



Right leg L3 / 4 radiculopathy



Reflex Sympathetic Dystrophy (Complex Regional Pain)

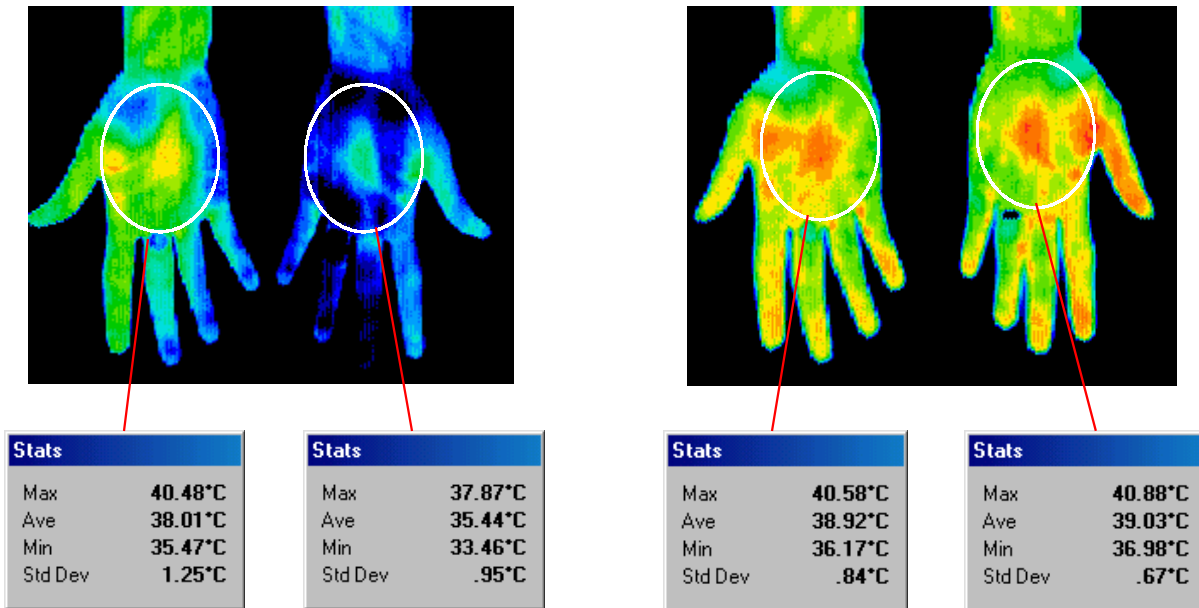
The very definition of RSD is still controversial in some quarters. Many practitioners question the diagnosis of the condition due to lack of objective and reliable evidence. Hooshmand (1993) in his encyclopaedic work, “Chronic Pain: Reflex Sympathetic Dystrophy. Prevention and Management”, states that ‘Infrared Thermography is the most sensitive test in the diagnosis of RSD’. He goes on to state that no other testing modality can match thermography in the detection of RSD.

RSD has a very distinct DITI signature, where there is a well defined border to the hypothermic zone, which will normally give a ‘glove’ or “sock” like image of hypothermia. In cases where RSD is suspected, a cold challenge stress test is applied.

The suspect area is scanned for thermal stability, and once established a cold challenge is applied. The patient has a non-affected body part immersed in water of approx. 4 degrees Centigrade. This causes the sympathetic nervous system to respond, and restrict the micro-dermal circulation over the body. This sympathetic vasoconstriction will not be observed in an area demonstrating true RSD. If the symptomatic area shows any reduction in temperature over the three minutes of the cold challenge, RSD is determined not to be affecting the area. This tends towards the idea of a “simple” neuropathy. The reliability of the cold stress is guaranteed by the simultaneous scanning of asymptomatic zones, and ensuring that these zones respond with a reduced vaso-motion response.

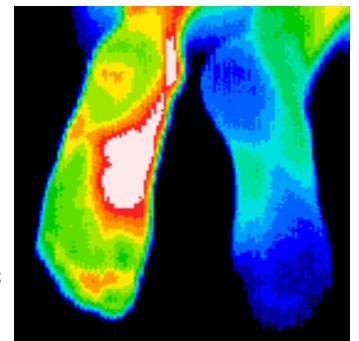
RSD patient with a 'glove like' hypothermia of the left hand. A temperature differential of 1.5 °c is considered significant, this patient presented with a 5 °c asymmetry. Cold stress test showed sympathetic function in the right hand but non in the left.

After treatment thermography showed good thermal symmetry and cold stress showed sympathetic function in both hands.



Complex Regional Pain Syndrome right foot, significant increase in sympathetic motor tone right foot 3.7°c colder than left foot. A cold stress test was positive, (no sympathetic change).

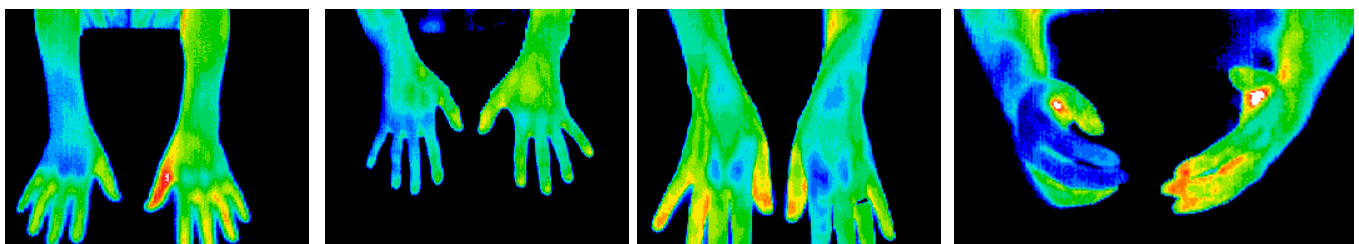
CRPS developed in the right foot after a fractured calcaneum 18 months previously. Weight bearing was painful. The diagnosis of CRPS was missed initially since nuclear imaging was not typical of CRPS. Some cases of CRPS are misdiagnosed as psychological or hysterical pain states. Thermography is able to show characteristic changes if utilized.



Neuropathological Referrals

Neuropathological factors in clinical assessments are made difficult by the requirement for subjective patient description of their sensations. Because DITI yields objective results, reliance on a patient's subjective reporting is far lessened, and the practitioner is able to better understand and scale the reported symptoms.

Factors capable of interfering with the transmission of action potential will show an asymmetrical thermal signature along the path of that nerve. The neural vasomotion factors will typically exhibit alteration along a specific dermatomal pathway in the case of vertebro-costal problems, and in the specific regions of supply for problems interfering with discrete nerve pathways.



Vascular Phenomena

Angiogenesis

Neoplastic alterations of cells have demonstrated accompanying high levels of interstitial angiogenic stimulating compounds, particularly of the prostaglandin types (PEG1 & PEG2). Gullino (1992) states 'The thin walled vessels that are present in tumours consist almost entirely of basement membrane with a single cell layer, i.e. endothelium.' He goes on further to state, 'the newly formed vessels produce a chaotic, disorganised network, with tortuous vessels, often sinusoidal in nature and always thin walled, traversing the tumour mass. It seems likely that the rare vessels seen in a tumour with a well-developed multi-layered wall are those that have been parasitised and engulfed by the expanding tumour mass.' (pp. 160-161)

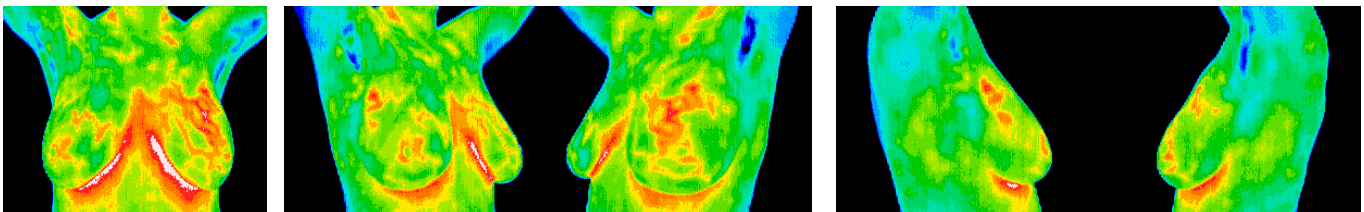
In suitable tissues (the breast in particular), these factors combine to exhibit a clear thermal signature due to

- Increases in vessel size servicing the neoplasm form a demonstrable DITI asymmetry.
- The chaotic nature of the capillary structure leads to a lack of graduated thermal transition ('smooth' thermal signature), as expected in normal tissues.
- The lack of smooth muscle tissue in the neovascularity demonstrates a comparative vasomotion thermal signature that does not respond in similar fashion to the surrounding 'normal' vascular structures. Eliciting a sympathetic constrictive response by immersion of a body part (usually a hand and wrist) in cold water will demonstrate a vasomotion differential in the effected area.
- In more advanced neoplastic formations, the chaotic tissue structure with depressed metabolism in tissues removed from the vascular supply will often demonstrate a hypothermic core. Depending on position, the hypothermic displacement will show in a DITI scan.

Many of the so-called 'false positives' of DITI breast screening are often 'true positive' findings of angiogenesis preceding actual tumour development. Detection in these early stages is unreliable by conventional means, often due to the fact that the tumour has not developed sufficient density.

DITI breast screening is particularly useful to:

- Women who are under 40
- Women who for any reason can not or will not have a mammogram
- Women who are outside of the mammographic screening guidelines due to surgical procedures or contra indicating reasons.



Standard views for a breast study: vascular patterns in the upper quadrants of the left breast are consistent with angiogenesis and would justify further investigation and regular comparative thermography to monitor changes.

Sample one page Report

REPORT

Patient:
Date of Birth: #
Referring Doctor:

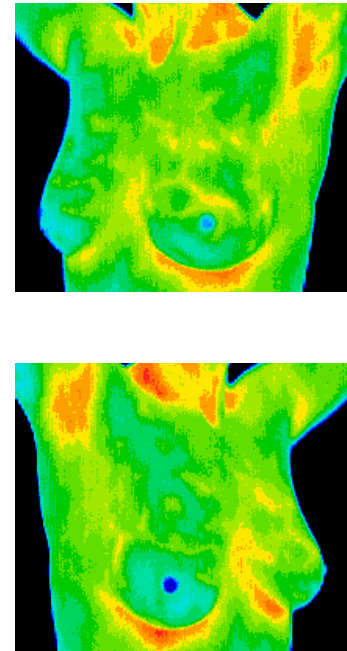
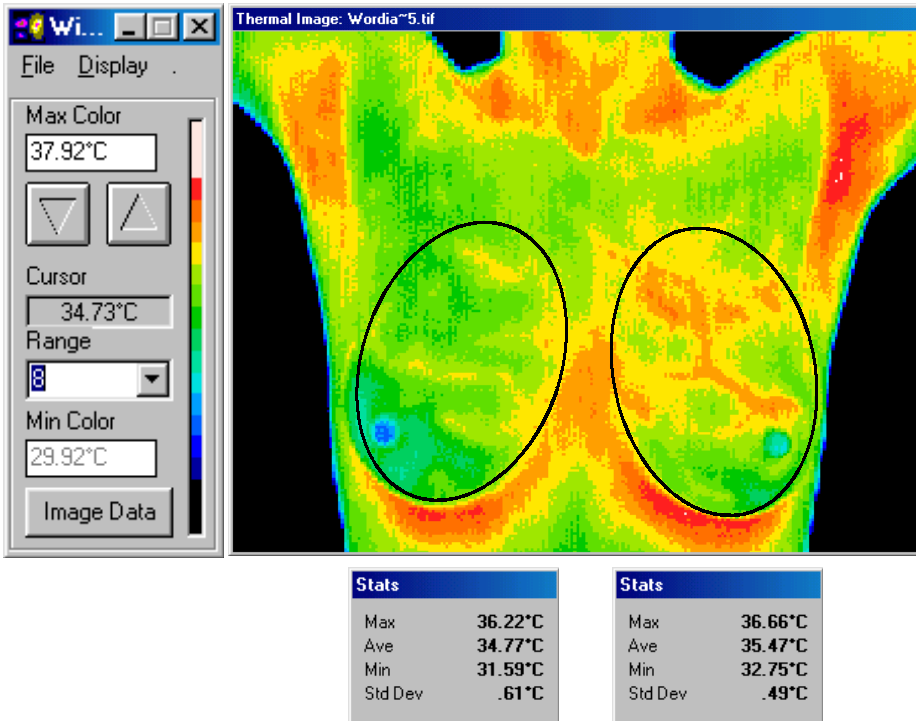
Scan Date:
Scan Ref:
Clinical Thermographer:

Clinical Notes from patient : Fibrocystic changes in upper left breast.

All normal protocols were observed.

Reported By :

There are slight patterns of hyperthermia in the upper inner quadrant of the left breast. Temperature differentials are not particularly significant and there is not remarkable vascular activity. These patterns appear consistent with findings relating to fibrocystic tissue, suggest clinical correlation. This study is suitable to be archived and compared with a repeat study in three months to establish a baseline, prior to annual testing.*



Breast thermography is a way of monitoring breast health over time. Normal breasts have a stable thermographic pattern that does not change over time (much like a fingerprint). The purpose of the initial breast study is to establish the normal baseline pattern for each individual patient to which all future thermograms are compared. With usual breast health, the thermograms remain identical to the initial study. Any changes recorded can mean that there may be functional changes within the breast that call for further investigation. The ability to interpret an initial study is limited since there are no previous images for comparison. Sometimes patterns are complex enough that we may suggest that clinical correlation, mammography, and/or ultrasound be done in order to be more confident that this is the patient's healthy baseline pattern.

Sample EMI Report



Electronic Medical Interpretation Inc.

Report

Page 1 of 3

Electronic Medical
Interpretation Inc.
316 State Street,
Bangor
Maine 04401 USA
Ph. 207-942-2233

Patient: xxxxxxxx
Date of Birth: 09/18/1953
Patient ID: 2191

Scan Date: 7/11/2001
Report Ref: 11051
Report Type: Breast

Ronald L Blum M.D.
FACOEM. FAAFP.

Linda Hegstrand M.D.
Ph.D

Peter Leando Ph.D
D.Sc. D.Ac.

Lauren Swerdloff M.D.

Jim Blum Ph.D.

Monte Elgarten M.D.

Arlette Pharo D.O.

All normal protocols were observed

Reported By: Monte Elgarten MD.

PROCEDURE: This patient was examined with digital infrared thermal imaging to determine if asymmetrical thermal findings indicate abnormal physiology.

Thermography as a physiologic test, demonstrates heat patterns that are strongly indicative of breast abnormality, the test can detect subtle changes in breast temperature that indicate a variety of breast diseases and abnormalities and once abnormal heat patterns are detected in the breast, follow-up procedures including mammography are necessary to rule out or properly diagnose a number of breast diseases such as fibrocystic syndrome etc.

Breast thermography is a way of monitoring breast health over time. Normal breasts have a stable thermographic pattern that does not change over time (much like a fingerprint). The purpose of the initial breast study is to establish the normal baseline pattern for each individual patient to which all future thermograms are compared. With continued breast health, the thermograms remain identical to the initial study. Any changes recorded can mean that there may be physiological changes within the breast that call for further investigation. The ability to interpret an initial study is limited since there are no previous images for comparison. Sometimes patterns are complex enough that we may suggest that clinical correlation, mammography, and/or ultrasound be done in order to be more confident that this is the patient's healthy baseline pattern.

This exam is an adjunctive diagnostic procedure and all interpretive findings must be clinically correlated.

PROTOCOLS: The thermographer certifies that this exam was conducted under all standard and clinically acceptable protocols.

EXAM RESULTS: Exam results are reported by certified thermologists. Results are determined by studying the varying patterns and temperature differentials as recorded in the thermal images.

NORMAL VALUES: Diffuse heat patterns with good symmetry between contra-lateral regions of the breasts. Specific asymmetries that have remained stable and unchanged over time and have been regarded as a normal part of this patients thermal anatomy.

ABNORMAL VALUES: Localized areas of hyperthermia or hypothermia, thermal asymmetry between contra-lateral regions of the breasts with temperature differentials of more than 1° C. Vascular patterns that appear suspicious. Any thermal changes that are recorded during comparative analysis over time.

COLD STRESS: If a cold stress test has been considered appropriate to evaluate sympathetic response to a suspicious vascular pattern to evaluate the possibility of angiogenesis. Positive = no thermal change to the suspicious pattern during normal change to other areas of the breasts. Negative = normal thermal change to all areas of the breasts including the suspicious pattern. (results of cold stress testing are not considered conclusive or diagnostic).

REPORT: This report relates to objective descriptions of thermal asymmetries with regard to the patient information and history provided, and findings that might be clinically significant.

There is an area of hyperthermia seen in the upper outer quadrant of the left breast but there are no other significant thermal asymmetries of the breasts. There is no indication of any neovascularity or suspicious thermal findings relating to the pathology currently being treated.

This study is suitable to be archived as a base-line for future comparison.

FOLLOW-UP: Referring patient back to practitioner. Suggest routine follow-up in three months before continuing with annual comparative studies.


The referring physician should contact the EMI administrator with any questions relating to this report.

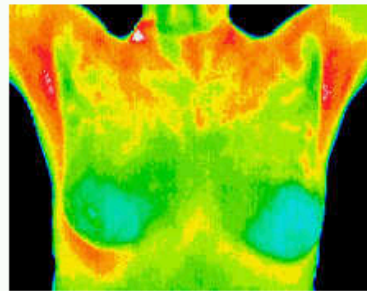
This Report is intended for use by trained health providers to assist in evaluation, diagnosis, and treatment. It is not intended for use by individuals for self-evaluation or self-diagnosis. This Report does not provide a diagnosis of illness, disease or other condition.

THERMOGRAMS

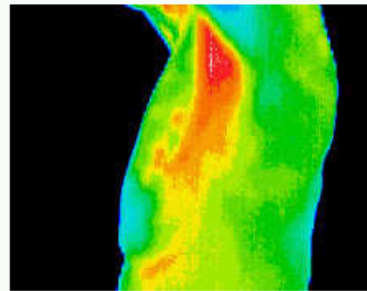
Patient: [REDACTED]
Date of Birth: 09/05/1939
Patient ID: 3809
Referring Practitioner: [REDACTED]

Scan Date: 11/29/2001
Report Ref: 12687
Report Type: Breast
Thermographer: [REDACTED]

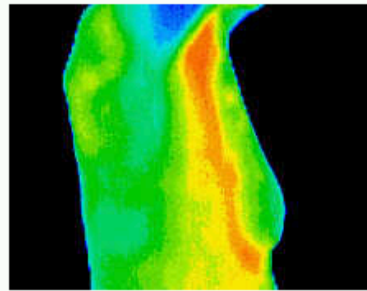
+ -
 thermograms @ standard 8° C color range



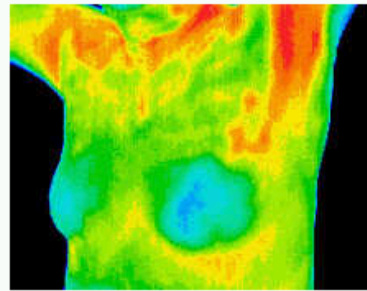
TayShi112901A2BA



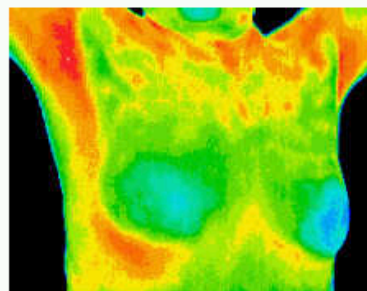
TayShi112901A2BLL



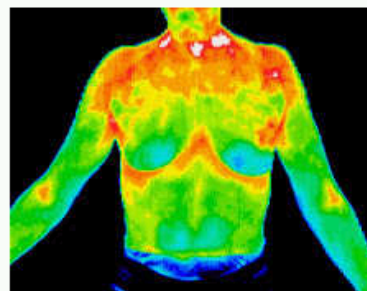
TayShi112901A2BLR



TayShi112901A2BOL



TayShi112901A2BOR



TayShi112901AA

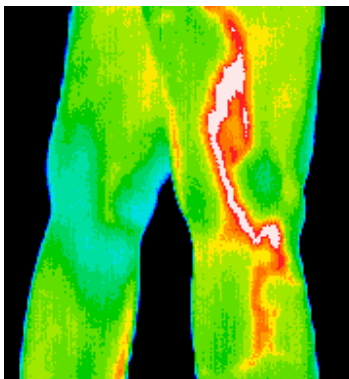
Thrombophlebitis & DVT

Thrombophlebitis is a common cause of pain in situations of varicose veins, especially in deep phenomena. Painful legs are one of the most common presenting complaints in this condition. Practitioners suspecting phlebitis can refer for a simple DITI scan to confirm or rule out the presence of varicosities.

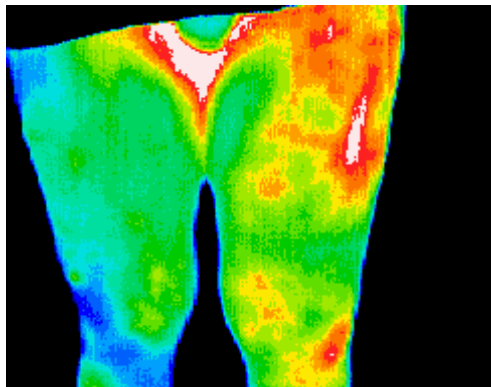
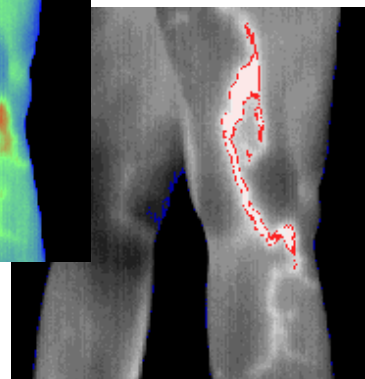
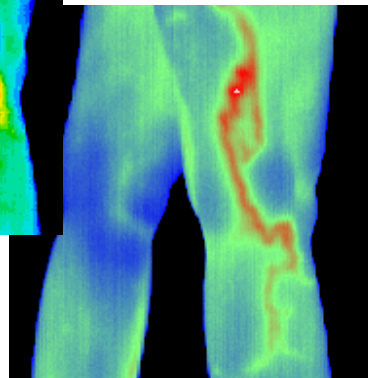
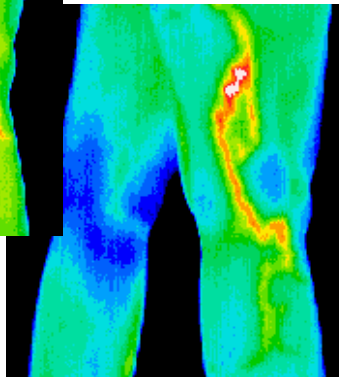
Increase in venous diameter results in increased volume, decreased serous velocity and often inflammation. The increase in comparatively warmer blood (volume) contrasts with the surrounding 'normal' tissues with typical vascular patterns. The sympathetic reflection of the inflammatory process, and the increase in relative temperature stands out spectacularly in a DITI scan.

DVT is a concern for all practitioners. The symptoms of DVT are equivocal in many cases, and best practice often requires caution to the point of excess. Pharmaceutical agents are often prescribed prior to definitive imaging evidence of the presence of DVT, typically by Doppler ultrasound.

DITI is capable of clearly visualising an enlarged and inflamed vein. A patient with a symptomatic presentation supporting the suspicion of DVT can have an economical DITI scan, and if the scan is returned as positive for a varicosity, then a far more expensive Doppler ultrasound is justified. This good visualisation capability of varices gives DITI a very high level of negative prediction screening reliability.



Vascular patterns can be seen very graphically with thermography and the use of different colour maps help to emphasize particular Patterns, even to the point of identifying the location of perforators



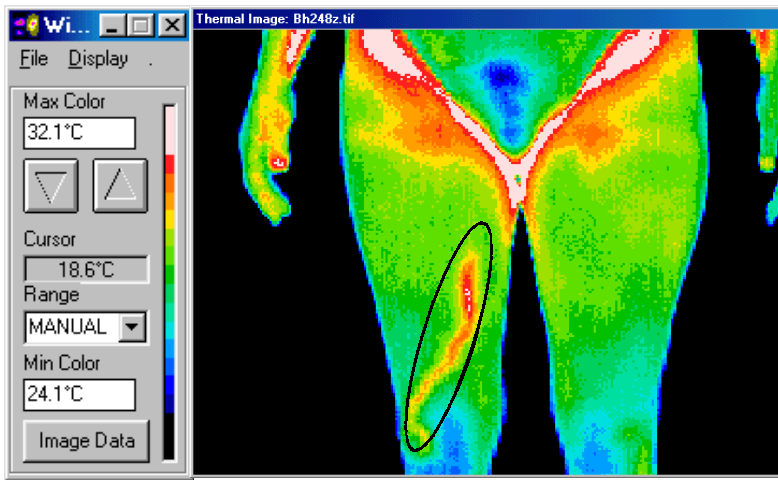
Elderly female patient two months post surgery (total hip) pain throughout upper left leg, suspected DVT, referred for thermography assessment before invasive testing or treatment ordered

Thermography report showing a focal point of inflammation helped the ultasonographer confirm a deep abscess which was drained. Antibiotic treatment was proscribed instead of anticoagulants.

Normally the temperature of the two legs is equal at the same level, with a gradual cooling of 4°C from the inguinal region to the feet.

If there is a homogenous area of increased temperature in the calf together with loss of pretibial coolness this indicates a thrombosis in the calf veins.

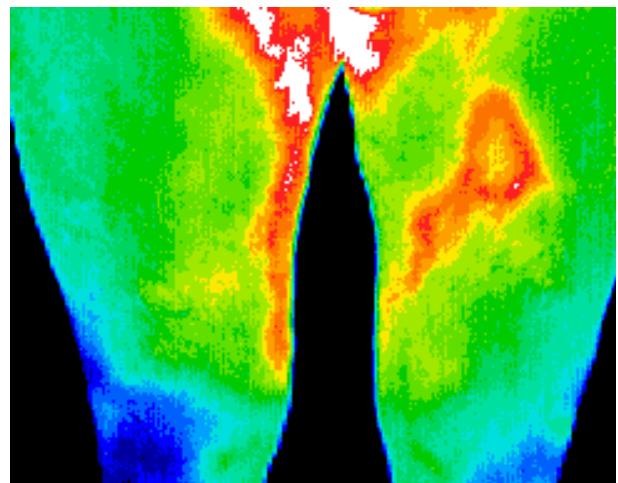
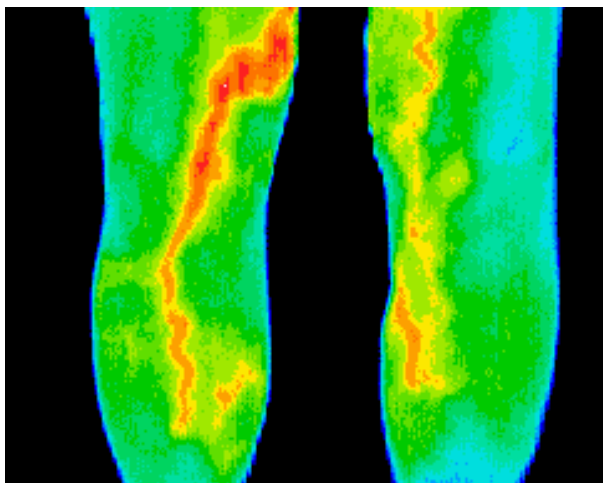
Positive Thermogram scan shows deep varicosity - unable to be seen on skin's surface



Outpatients commonly present with pain and/or swelling of the lower extremity. Inpatients may offer similar complaints, but more often the attending physician is alerted by swelling, warmth, redness, or venous engorgement of the leg or thigh. When risk factor knowledge and examination findings lead the physician to be "suspicious" for DVT, he/she must then decide between alternative courses.

Loss of prepatellar coolness implies a thrombosis in the popliteal vein and a diffuse rise in the thigh indicates a femoral vein thrombus.

Loss of the normal temperature gradient indicates probable bilateral deep vein thrombosis.



Ischaemic Phenomena

Conditions in which arterial blood flow is reduced can typically be seen by DITI scanning. Disruptions to appendicular vessels in particular are easily visualised with DITI scanning in most cases.

A rule out ischaemia DITI scan is performed in three phases, generally taking around forty-five minutes. The first part involves imaging the symptomatic area, and its contralateral partner, as well as the vertebral innervation and primary arterial supply of the area in question.

The next part of the test involves having the patient duplicate activity that typically causes the symptoms to manifest (walk on a treadmill in the case of a femoral artery). Images of the problematic area whilst the symptoms are manifesting are captured. The last phase consists of imaging the area fifteen minutes after cessation of activity. Scan comparison gives a strong opportunity to support the theory of the pain being of ischaemic or neural aetiology. In situations where a patient's complaint is suggestive of an ischaemic problem, a DITI scan can quickly contribute solid objective data towards a practitioner's diagnosis.

References.

- Altchek EM; Medical thermography and its use in posttraumatic cephalagia. (Int. Neurosci, 1990 Sep)
- Baglin TP; Bone marrow hypervascularity in patients with myelofibrosis identified by infra-red thermography. (Clin Lab Haematol, 1991)
- Ben-Eliyahu DJ; Infrared thermographic imaging in the detection of sympathetic dysfunction in patients with patellofemoral pain syndrome [published erratum appears in J Manipulative Physiol Ther 1992 Jul-Aug;15(6):preceding table of contents] (J Manipulative Physiol Ther, 1992 Mar-Apr)
- Birdi N; Childhood linear scleroderma: a possible role of thermography for evaluation. (J Rheumatol, 1992 Jun)
- Bruehl S; Validation of thermography in the diagnosis of reflex sympathetic dystrophy. (Clin J Pain, 1996 Dec)
- Canavan D; Electronic thermography for the assessment of mild and moderate temporomandibular joint dysfunction. (Oral Surg Oral Med Oral Pathol Oral Radiol Endod, 1995 Jun)
- Chan EK; Visualization of dynamic subcutaneous vasomotor response by computer-assisted thermography. (IEEE Trans Biomed Eng, 1990 Aug)
- Chan FH; Generation of three-dimensional medical thermograms. (Biomed Mater Eng, 1996)
- Chan FH; Thyroid diagnosis by thermogram sequence analysis. (Biomed Mater Eng, 1995)
- Cline M, Ochoa J, Torebjork E; Chronic hyperalgesia and skin warming caused by sensitized c nociceptors. (Brain, 1989)
- Cole RP; Thermographic assessment of hand burns. (Burns, 1990 Feb)
- Cooke ED; Reflex sympathetic dystrophy and repetitive strain injury: temperature and microcirculatory changes following mild cold stress. (J R Soc Med, 1993 Dec)
- Dalla Volta G; The disappearance of the "cold patch" in recovered migraine patients: thermographic findings (Headache, 1991 May)
- Darton K; The use of infra-red thermography in a rheumatology unit (Br J Rheumatol, 1990 Aug)
- Devulder J; Epidural spinal cord stimulation does not improve microvascular blood flow in neuropathic pain. (Angiology, 1996 Dec)
- Devulder J; Infra-red thermographic evaluation of spinal cord electrostimulation in patients with chronic pain after failed back surgery. (Br J Neurosurg, 1996 Aug)
- Diakow PR; Differentiation of active and latent trigger points by thermography. (J Manipulative Physiol Ther, 1992 Sep)
- Dotson R, Ochoa J, Marchetti P, Cline M; Sympathetic neural outflow directly recorded in patients with primary autonomic failure. (Neurology, 1990;40:1079-1085)
- Emery RW; Revascularization using angioplasty and minimally invasive techniques documented by thermal imaging. (Ann Thorac Surg, 1996 Aug)

Feldman F, Nickoloff D.; Normal thermographic standards for the cervical spine and upper extremities. (International Skeletal Society 1984)

Feldman F; Thermography of the hand and wrist: practical applications. (Hand Clin, 1991 Feb)

Friedman MS; The use of thermography in sympathetically maintained pain. (Iowa Orthop J, 1994)

Garagiola U; Telethermography and Raynaud's phenomenon. (J Sports Med Phys Fitness, 1991 Mar)

Garagiola U; Use of telethermography in the management of sports injuries. (Sports Med, 1990 Oct)

Geatti O; A comparison of scintigraphy, thermography, ultrasound and phlebography in grading of clinical varicocele. (J Nucl Med, 1991 Nov)

Graff-Radford SB; Thermographic assessment of neuropathic facial pain. (J Orofac Pain, 1995 Spring)

Gratt BM; Electronic thermography in the assessment of internal derangement of the temporomandibular joint. A pilot study. (Oral Surg Oral Med Oral Pathol, 1991 Mar)

Gratt BM; Future applications of electronic thermography. (J Am Dent Assoc, 1991 May)

Gratt BM; Thermographic assessment of craniomandibular disorders: diagnostic interpretation versus temperature measurement analysis. (J Orofac Pain, 1994 Summer)

Gratt BM; Thermographic characterization of osteoarthritis of the temporomandibular joint. (J Orofac Pain, 1993 Fall)

Gratt BM; Thermographic characterization of the asymptomatic temporomandibular joint. (J Orofac Pain, 1993 Winter)

Greenstein D; Assessment of chemical lumbar sympathectomy in critical limb ischaemia using thermal imaging. (Int J Clin Monit Comput, 1994 Feb)

Gross EJ; Experimental assessment of phased-array heating of neck tumours. (Int J Hyperthermia, 1990 Mar-Apr)

Harper CM Jr; Utility of thermography in the diagnosis of lumbosacral radiculopathy (Neurology, 1991 Jul)

Hauer JL; Hand skin blood flow in diabetic patients with autonomic neuropathy and microangiopathy. (Diabetes Care, 1991 Oct)

Head JF; Breast thermography is a noninvasive prognostic procedure that predicts tumor growth rate in breast cancer patients. (Ann N Y Acad Sci, 1993 Nov 30)

Herrick A; Abnormal thermoregulatory responses in patients with reflex sympathetic dystrophy syndrome. (J Rheumatol, 1994 Jul)

Heywang-Köbrunner SH; Nonmammographic breast imaging techniques. (Curr Opin Radiol, 1992 Oct)

Hsieh JC; Clinical application of infrared thermography in diagnosis and therapeutic assessment of vascular ischemic pain [published erratum appears in Ma Tsui Hsueh Tsa Chi 1991 Mar;29(1):567] (Ma Tsui Hsueh Tsa Chi, 1990 Dec)

Hunold S; Thermographic studies on patterns of skin temperature after exercise. (Eur J Appl Physiol, 1992)

Itoh Y; Use of recovery-enhanced thermography to localize cutaneous perforators. (Ann Plast Surg, 1995 May)

Iwata G; Thermography in a child with varicocele. (Eur J Pediatr Surg, 1992 Oct)

Janssens LA; Trigger point therapy. (Probl Vet Med, 1992 Mar)

Jeracitano D; Abnormal temperature control suggesting sympathetic dysfunction in the shoulder skin of patients with frozen shoulder. (Br J Rheumatol, 1992 Aug)

Karstetter KW; Use of thermography for initial detection of early reflex sympathetic dystrophy. (J Am Podiatr Med Assoc, 1991 Apr)

Katoh K; Use of prostaglandin E1 (lipo-PGE1) to treat Raynaud's phenomenon associated with connective tissue disease: thermographic and subjective assessment. (J Pharm Pharmacol, 1992 May)

Kruse RA Jr; Thermographic imaging of myofascial trigger points: a follow-up study. (Arch Phys Med Rehabil, 1992 Sep)

Kyle V; Rarity of synovitis in polymyalgia rheumatica (Ann Rheum Dis, 1990 Mar)

Lawson W; Infrared thermography in the detection and management of coronary artery disease. (Am J Cardiol, 1993 Oct 15)

Leclaire R; Diagnostic accuracy of technologies used in low back pain assessment. Thermography, triaxial dynamometry, spinoscopy, and clinical examination. (Spine, 1996 Jun 1)

Liddington MI; Timing of the thermographic assessment of burns. (Burns, 1996 Feb)

MacDonald AG; Microwave thermography as a noninvasive assessment of disease activity in inflammatory arthritis. (Clin Rheumatol, 1994 Dec)

Magerl W; Asymmetry and time-course of cutaneous sympathetic reflex responses following sustained excitation of chemosensitive nociceptors in humans. (J Auton Nerv Syst, 1996 Feb 5)

Mannara G; Ethyl alcohol induced skin temperature changes evaluated by thermography. Preliminary results. (Boll Soc Ital Biol Sper, 1993 Oct)

Matsumura H; Haemodynamic changes in early phase reflex sympathetic dystrophy. (Scand J Plast Reconstr Surg Hand Surg, 1996 Jun)

McBeth SB; Thermographic assessment of temporomandibular disorders symptomology during orthodontic treatment. (Am J Orthod Dentofacial Orthop, 1996 May)

McCulloch J; Thermography as a diagnostic aid in sciatica. (J Spinal Disord, 1993 Oct)

McKinna JA; The early diagnosis of breast cancer--a twenty-year experience at the Royal Marsden Hospital. (Eur J Cancer, 1992)

Menachem A; Levator scapulae syndrome: an anatomic-clinical study. (Bull Hosp Jt Dis, 1993 Spring)

Mirza N; Influence of age on the 'nasal cycle'. (Laryngoscope, 1997 Jan)

O'Reilly D; Measurement of cold challenge responses in primary Raynaud's phenomenon and Raynaud's phenomenon associated with systemic sclerosis. (Ann Rheum Dis, 1992 Nov)

Park ES; Comparison of sympathetic skin response and digital infrared thermographic imaging in peripheral neuropathy. (Yonsei Med J, 1994 Dec)

Pawl RP; Thermography in the diagnosis of low back pain. (Neurosurg Clin N Am, 1991 Oct)

Pierart J; Use of thermography in the differential diagnosis of phylloides tumour. (Br J Surg, 1990 Jul)

Ping Z; Correlation study on infrared thermography and nerve root signs in lumbar intervertebral disk herniation patient: a short report [published erratum appears in J Manipulative Physiol Ther 1993 Oct;16(8):560] (J Manipulative Physiol Ther, 1993 Mar-Apr)

Plaughner G; Skin temperature assessment for neuromusculoskeletal abnormalities of the spinal column. (J Manipulative Physiol Ther, 1992 Jul-Aug)

Raj P; Practical Management of Pain. Mosby Year Book Inc. 1992

Ramlau C; Combination of thermographic and ultrasound methods for the diagnosis of female breast cancer. (Eur J Gynaecol Oncol, 1993)

Seifalian AM; Comparison of laser Doppler perfusion imaging, laser Doppler flowmetry, and thermographic imaging for assessment of blood flow in human skin. (Eur J Vasc Surg, 1994 Jan)

Seppely M; Facial thermography during nasal provocation tests with histamine and allergen. (Allergy, 1993 Jul)

Sheinberg M; Application of telethermography in the evaluation of preterm premature rupture of the fetal membranes. (Biomed Instrum Technol, 1996 Nov-Dec)

Shetty V; Thermographic assessment of reversible inferior alveolar nerve deficit. (J Orofac Pain, 1994 Fall)

Sterns EE; Thermography as a predictor of prognosis in cancer of the breast. (Cancer, 1991 Mar 15)

Sterns EE; Thermography. Its relation to pathologic characteristics, vascularity, proliferation rate, and survival of patients with invasive ductal carcinoma of the breast. (Cancer, 1996 Apr 1)

Sterns EE; Vascularity demonstrated by Doppler ultrasound and immunohistochemistry in invasive ductal carcinoma of the breast. (Breast Cancer Res Treat, 1996)

Strong WE; Does the sympathetic block outlast sensory block: a thermographic evaluation. (Pain, 1991 Aug)

Sucher BM; Thoracic outlet syndrome--a myofascial variant: Part 1. Pathology and diagnosis. (J Am Osteopath Assoc, 1990 Aug)

Takahashi Y; Thermal deficit in lumbar radiculopathy. Correlations with pain and neurologic signs and its value for assessing symptomatic severity. (Spine, 1994 Nov 1)

Tchou S; Thermographic observations in unilateral carpal tunnel syndrome: report of 61 cases. (J Hand Surg [Am], 1992 Jul)

Thomas D; Computerised infrared thermography and isotopic bone scanning in tennis elbow. (Ann Rheum Dis, 1992 Jan)

Thomas D; Infrared thermographic imaging, magnetic resonance imaging, CT scan and myelography in low back pain. (Br J Rheumatol, 1990 Aug)

Thomas D; Somatic sympathetic vasomotor changes documented by medical thermographic imaging during acupuncture analgesia. (Clin Rheumatol, 1992 Mar)

Ulmer HU; Thermography in the follow-up of breast cancer patients after breast-conserving treatment by tumorectomy and radiation therapy. (Cancer, 1990 Jun 15)

Vecchio PC; Thermography of frozen shoulder and rotator cuff tendinitis. (Clin Rheumatol, 1992 Sep)

Verdugo RJ; Use and misuse of conventional electrodiagnosis, quantitative sensory testing, thermography, and nerve blocks in the evaluation of painful neuropathic syndromes. (Muscle Nerve, 1993 Oct)

Vujci M; Thermography in the detection and follow up of chondromalacia patellae. (Ann Rheum Dis, 1991 Dec)

Weinstein SA; Facial thermography, basis, protocol, and clinical value. (Cranio, 1991 Jul)

Weinstein SA; Thermophysiological anthropometry of the face in Homo sapiens. (Cranio, 1990 Jul)

Williams KL; Thermography in screening for breast cancer. (J Epidemiol Community Health, 1990 Jun)

Winsor D; Comparison of various noninvasive techniques for evaluating deep venous thrombosis. (Angiology, 1991 Oct)

Yang WJ; Literature survey on biomedical applications of thermography. (Biomed Mater Eng, 1992 Spring)

Zhang D; Clinical observations on acupuncture treatment of peripheral facial paralysis aided by infra-red thermography--a preliminary report. (J Tradit Chin Med, 1991 Jun)

Zhang D; Research on the acupuncture principles and meridian phenomena by means of infrared thermography. (Chen Tzu Yen Chiu, 1990)

INFORMATIONAL REPORT OF THE COUNCIL ON SCIENTIFIC AFFAIRS Thermography in Neurological and Musculoskeletal Conditions John H. Moxley, III, M.D., Chairman

INDICATIONS FOR A THERMOGRAPHIC EVALUATION:

Alphabetic order

Altered Ambulatory Kinetics	Nerve Entrapment
Altered Biokinetics	Nerve Impingement
Arteriosclerosis	Nerve Pressure
Brachial Plexus Injury	Nerve Root Irritation
Biomechanical Impropriety	Nerve Stretch Injury
Breast Disease	Nerve Trauma
Bursitis	Neuropathy
Carpal Tunnel Syndrome	Neurovascular Compression
Causalgia	Neuralgia
Compartment Syndromes	Neuritis
Cord Pain/Injury	Neuropraxia
Deep Vascular Disease	Neoplasia
Disc Disease	(melanoma, squamous cell, basal)
Disc Syndromes	Nutritional Disease
Dystrophy	(Alcoholism,Diabetes)
External Carotid Insufficiency	Peripheral Nerve Injury
Facet Syndromes	Peripheral Axon Disease
Grafts	Raynaud's
Hysteria	Referred Pain Syndrome
Headache Evaluation	Reflex Sympathetic Dystrophy
Herniated Disc	Ruptured Disc
Herniated Nucleus Pulposus	Somatization disorders
Hyperaesthesia	Soft Tissue Injury
Hyperextension Injury	Sprain/Strain
Hyperflexion Injury	Stroke Screening
Inflammatory Disease	Synovitis
Internal Carotid Insufficiency	Sensory Loss
Infectious Disease (Shingles, Leprosy)	Sensory Nerve Abnormality
Lumbosacral Plexus Injury	Somatic Abnormality
Ligament Tear	Superficial Vascular Disease
Lower Motor Neuron Disease	Skin Abnormalities
Lupus	Thoracic Outlet Syndrome
Malingering	Temporal Arteritis
Median Nerve Neuropathy	Trigeminal Neuralgia
Morton's Neuroma	Trigger Points
Myofascial Irritation	TMJ Dysfunction
Muscle Tear	Tendonitis
Musculoligamentous Spasm	Ulnar Nerve Entrapment
	Whiplash

All information given in the questionnaire will remain strictly confidential and will only be divulged to the reporting thermologist and any other practitioner that you specify.

Name: _____ **D.O.B:** _____

Address: _____

Phone: _____ **Doctor:** _____

Breast Thermography Confidential Questionnaire.

- Do you Smoke ? Yes: Never: Not in last 12 months: Not in last 5 years:
- Have you ever had a Mammogram ? No: Yes: How long ago (aprox years)
- Do you have any Children ? No: Yes: Your age at birth of first child:
- Do you have any close relative who has had breast cancer ? Yes: No:
- Have you ever had a non-malignant cystic breast disease ? Yes: No:
- Did your periods start before the age of 12 or finish after the age of 50 ? Yes: No:
- Have you ever had Hormone Replacement Therapy ? Yes: No:
- Have you ever had any breast cosmetic surgery or implants ? Yes: No:
- Have you ever taken a contraceptive pill for an extended time (over one year) ? Yes: No:
- Have you ever suffered from cancer of the womb ? Yes: No:
- Do you have an annual physical examination by a doctor ? Yes: No:
- Do you perform a monthly breast self examination ? Yes: No:

PATIENT DISCLOSURE

I understand that the Report generated from my images is intended for use by trained health care providers to assist in evaluation, diagnosis and treatment. I further understand that the Report is not intended to be used by individuals for self-evaluation or self-diagnosis.

I understand that the Report will not tell me whether I have any illness, disease, or other condition but will be an analysis of the Images with respect only to the thermographic findings of the areas discussed in the Report.

By signing below, I certify that I have read and understand the statements above and consent to the examination.

Signature

Full Body Study Questionnaire

All information given in the questionnaire will remain strictly confidential and will only be released to the reporting thermologist and any other practitioner that you specify.

Name: _____ D.O.B: _____

Address: _____

Phone: _____ Your Doctor: _____

Please Show areas of :

Main Pain



Secondary Pain



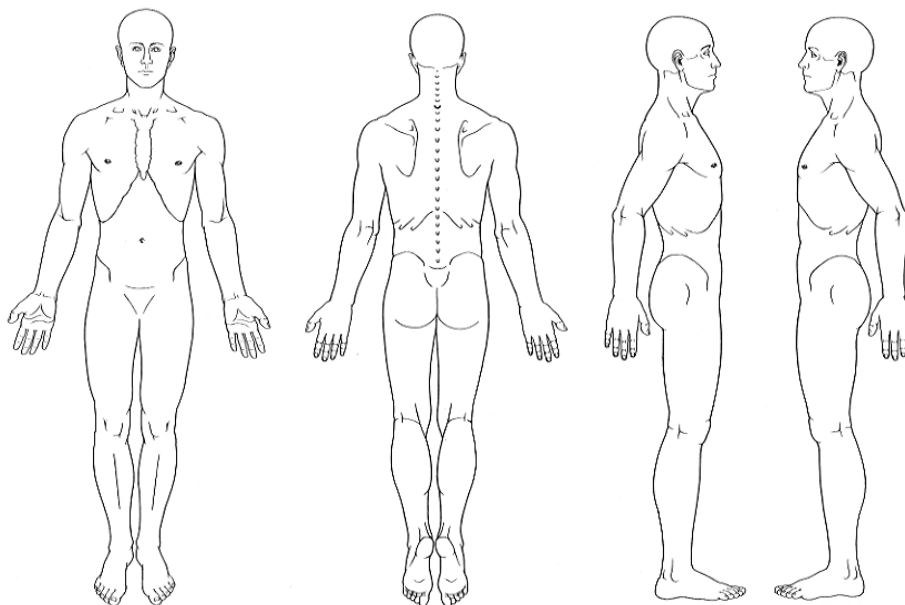
Numbness



Pins and needles



Skin lesions / scaring



Do you know what triggered the pain ?

Does anything relieve it ?

Does anything aggravate it ?

Has it changed since it began ?

Have you had any treatment ?

History: Injuries / Fractures / Surgery

PATIENT DISCLOSURE

I understand that the Report generated from my images is intended for use by trained health care providers to assist in evaluation, diagnosis and treatment. I further understand that the Report is not intended to be used by individuals for self-evaluation or self-diagnosis.

I understand that the Report will not tell me whether I have any illness, disease, or other condition but will be an analysis of the Images with respect only to the thermographic findings of the areas discussed in the Report.

By signing below, I certify that I have read and understand the statements above and consent to the examination.

Signature

Lower Body Study Questionnaire

All information given in the questionnaire will remain strictly confidential and will only be divulged to the reporting thermologist and any other practitioner that you specify.

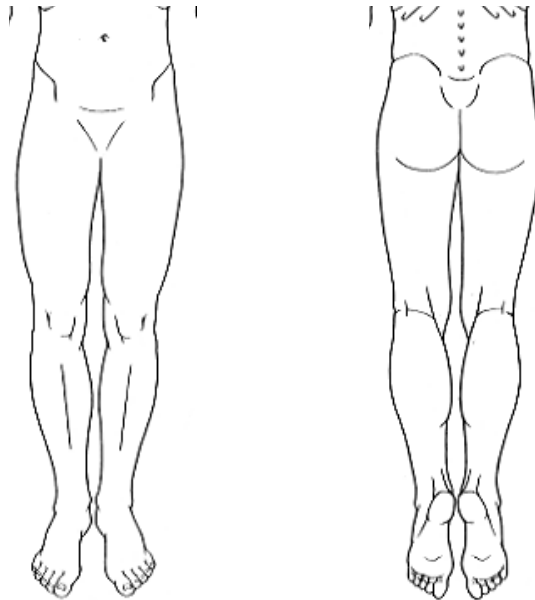
Name: _____ D.O.B: _____

Address: _____

Phone: _____ Your Doctor: _____

Please Show areas of :

- Main Pain *
- Secondary Pain ○
- Numbness //////////////
- Pins and needles :::::
- Skin lesions / scarring ↗



Do you know what triggered the pain ?

Does anything relieve it ?

Does anything aggravate it ?

Has it changed since it began ?

Have you had any treatment ?

History: Injuries / Fractures / Surgery

PATIENT DISCLOSURE

I understand that the Report generated from my images is intended for use by trained health care providers to assist in evaluation, diagnosis and treatment. I further understand that the Report is not intended to be used by individuals for self-evaluation or self-diagnosis.

I understand that the Report will not tell me whether I have any illness, disease, or other condition but will be an analysis of the Images with respect only to the thermographic findings of the areas discussed in the Report.

By signing below, I certify that I have read and understand the statements above and consent to the examination.

Signature

Upper Body Study Questionnaire

All information given in the questionnaire will remain strictly confidential and will only be divulged to the reporting thermologist and any other practitioner that you specify.

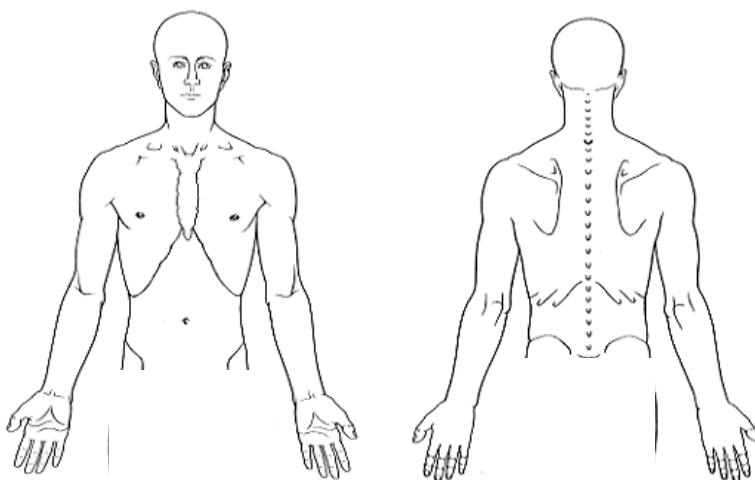
Name: _____ D.O.B: _____

Address: _____

Phone: _____ Your Doctor: _____

Please Show areas of :

- Main Pain *
- Secondary Pain ○
- Numbness //
- Pins and needles
- Skin lesions / scarring ↗



Do you know what triggered the pain ?

Does anything relieve it ?

Does anything aggravate it ?

Has it changed since it began ?

Have you had any treatment ?

History: Injuries / Fractures / Surgery

PATIENT DISCLOSURE

I understand that the Report generated from my images is intended for use by trained health care providers to assist in evaluation, diagnosis and treatment. I further understand that the Report is not intended to be used by individuals for self-evaluation or self-diagnosis.

I understand that the Report will not tell me whether I have any illness, disease, or other condition but will be an analysis of the Images with respect only to the thermographic findings of the areas discussed in the Report.

By signing below, I certify that I have read and understand the statements above and consent to the examination.

Signature

Region of Interest / Special Study Questionnaire

All information given in the questionnaire will remain strictly confidential and will only be divulged to the reporting thermologist and any other practitioner that you specify.

Name: _____ D.O.B: _____

Address: _____

Phone: _____ Your Doctor: _____

Please Show areas of :

Main Pain



Secondary Pain



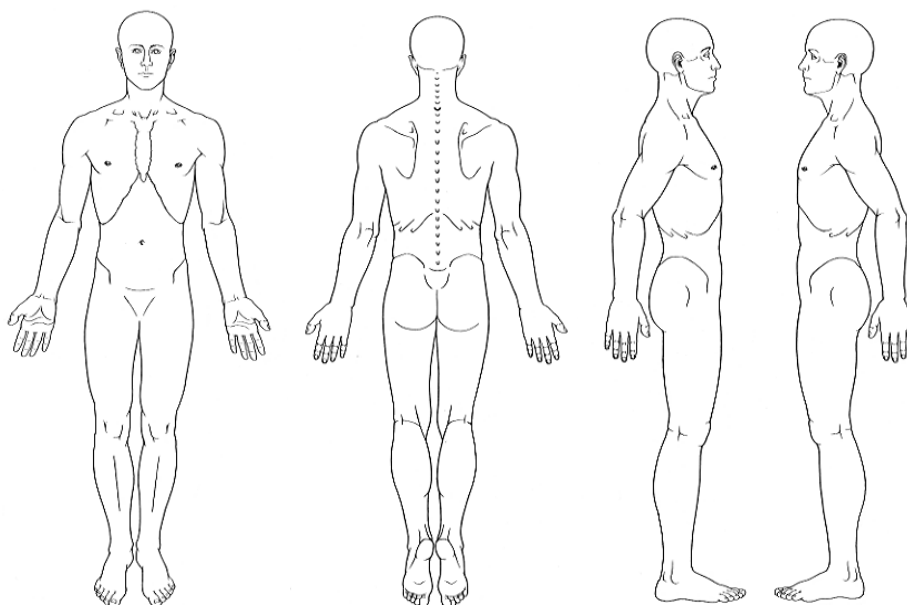
Numbness



Pins and needles



Skin lesions / scaring



Do you know what triggered the pain ?

Does anything relieve it ?

Does anything aggravate it ?

Has it changed since it began ?

Have you had any treatment ?

History: Injuries / Fractures / Surgery

PATIENT DISCLOSURE

I understand that the Report generated from my images is intended for use by trained health care providers to assist in evaluation, diagnosis and treatment. I further understand that the Report is not intended to be used by individuals for self-evaluation or self-diagnosis.

I understand that the Report will not tell me whether I have any illness, disease, or other condition but will be an analysis of the Images with respect only to the thermographic findings of the areas discussed in the Report.

By signing below, I certify that I have read and understand the statements above and consent to the examination.

Signature

Front

Meditherm Imaging

5 Kimbah Crt, Noosa, 4565. PHONE (07) 54742702 FAX (07) 54744044

Requesting Practitioner :

Copies of report to : *(address)*

Referring : _____

D.o.B : / /

Please indicate the region and study required

Pain evaluation

Breast imaging

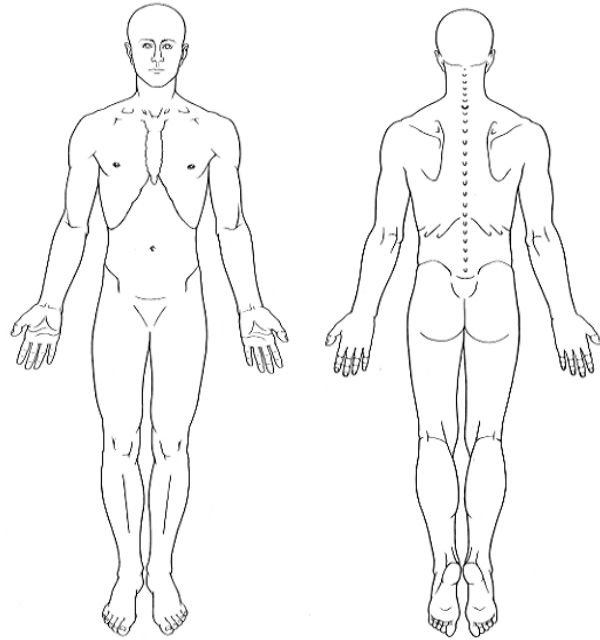
Treatment response
evaluation

Full body

Region of Interest

Cold stress test

Exercise stress test



Additional details :

Report required urgently

Patient Information — DITI Scanning

DITI (**D**igital **I**nfrared **T**hermal **I**maging) is non invasive, painless, non contact, and there is no radiation. DITI is a clinical imaging technique that records the thermal patterns of your body. Your thermal images are used by your healthcare practitioner to help diagnose and monitor pain or pathology in any part of your body.

Purpose of test:

- Help in determining cause of pain.
- For the early detection of disease and pathology.
- Evaluate sensory-nerve irritation or significant soft-tissue injury.
- To define a previously diagnosed injury or condition.
- To identify an abnormal area for further diagnostic testing.
- To follow progress of healing and rehabilitation.
- To provide objective evidence.

Patient preparation:

Do not have physical therapy or electromyography on the same day thermography is performed.

Activity - Do not smoke for 2 hours before the test, do not use lotions or liniments on day of test, stay out of strong sunlight day of test.

Diet - No changes necessary.

Medicines - No changes necessary.

Disrobing - You will be removing clothing down to pants. Removing jewelry. Putting on surgical gown.

Description of test:

Patient time for test: 15 — 30 minutes.

You are given time for your skin temperature to equalize with the room temperature. Examining rooms can be uncomfortably cool when you disrobe for the examination.

Thermal images are taken of the whole body, or just areas under investigation.

A lumbar assessment would typically include, low back, pelvis, and legs.

A cervical assessment would typically include, head and neck, upper trunk, and arms.

Neurological testing can include a "cold stress test", this just involves placing a hand or foot into a bowl of cool water, or having a cool gel pad applied to any part of the body.

You are welcome to have a partner or friend accompany you during the imaging

If you have any problem keeping your appointment, please let us know as soon as possible on (07) 5474 2702

A Review of Breast Thermography

Note: The following is not a comprehensive review of the literature. Over 30 years of research compiling over 800 studies in the index-medicus exist. What follows is a pertinent sample review of the research concerning the clinical application of diagnostic infrared imaging (thermography) for use in breast cancer screening. All the citations are taken from the index-medicus peer-reviewed research literature or medical textbooks. The authors are either PhD's with their doctorate in a representative field, or physicians primarily in the specialties of oncology, radiology, gynecology, and internal medicine.

The following list is a summary of the informational text that follows:

- In 1982, the FDA approved breast thermography as an adjunctive diagnostic breast cancer screening procedure.
- Breast thermography has undergone extensive research since the late 1950's.
- Over 800 peer-reviewed studies on breast thermography exist in the index-medicus literature.
- In this database, well over 300,000 women have been included as study participants.
- The numbers of participants in many studies are very large -- 10K, 37K, 60K, 85K
- Some of these studies have followed patients up to 12 years.
- Strict standardized interpretation protocols have been established for over 15 years.
- Breast thermography has an average sensitivity and specificity of 90%.
- An abnormal thermogram is 10 times more significant as a future risk indicator for breast cancer than a first order family history of the disease .
- A persistent abnormal thermogram carries with it a 22x higher risk of future breast cancer.
- An abnormal infrared image is the single most important marker of high risk for developing breast cancer.
- Breast thermography has the ability to detect the first signs that a cancer may be forming up to 10 years before any other procedure can detect it.
- Extensive clinical trials have shown that breast thermography significantly augments the long-term survival rates of its recipients by as much as 61%.
- When used as part of a multimodal approach (clinical examination + mammography + thermography) 95% of early stage cancers will be detected.

INTRODUCTION

The first recorded use of thermobiological diagnostics can be found in the writings of Hippocrates around 480 B.C. [1]. A mud slurry spread over the patient was observed for areas that would dry first and was thought to indicate underlying organ pathology. Since this time, continued research and clinical observations proved out that certain temperatures related to the human body were indeed indicative of normal and abnormal physiologic processes. In the 1950's, military research into infrared monitoring systems for night time troop movements ushered in a new era in thermal diagnostics. The first use of diagnostic thermography came in 1957 when R. Lawson discovered that the skin temperature over a cancer of the breast was higher than that of normal tissue [2]. The Department of Health Education and Welfare released a position paper in 1972 in which the director, Thomas Tiernery, wrote, "The medical consultants indicate that thermography, in its present state of development, is beyond the experimental state as a diagnostic procedure in the following 4 areas: (1) Pathology of the female breast. (2).....". On January 29, 1982, the Food and Drug Administration published its approval and classification of thermography as an adjunctive diagnostic screening procedure for the detection of breast cancer. Since the late 1970's, numerous medical centers and independent clinics have used thermography for diagnostic purposes.

FUNDAMENTALS OF INFRARED IMAGING

Physics -- All objects with a temperature above absolute zero (-273 K) emit infrared radiation from their surface. The Stefan-Boltzmann Law defines the relation between radiated energy and temperature by stating that the total radiation emitted by an object is directly proportional to the object's area and emissivity and the fourth power of its absolute temperature. Since the emissivity of human skin is extremely high (within 1% of that of a black body), measurements of infrared radiation emitted by the skin can be converted directly into accurate temperature values.

Equipment Considerations -- Infrared rays are found in the electromagnetic spectrum within the wavelengths of 0.75 micron - 1mm. Human skin emits infrared radiation mainly in the 2 - 20 micron wavelength range, with an average maximum of 10 microns [3]. State-of-the-art infrared radiation detection systems utilize ultra-sensitive infrared cameras and sophisticated computers to detect, analyze, and produce high-resolution diagnostic images of these in-

frared emissions. The problems encountered with first generation infrared camera systems such as improper detector sensitivity (low-band), thermal drift, calibration, analog interface, etc. have been solved for almost two decades.

Laboratory Considerations -- Thermographic examinations must be performed in a controlled environment. The main reason for this is the nature of human physiology. Changes from a different external (non-clinical controlled room) environment, clothing, etc. produce thermal artifacts. Refraining from sun exposure, stimulation or treatment of the breasts, and cosmetics and lotions before the exam, along with 15 minutes of nude acclimation in a florescent lit, draft and sunlight-free, temperature and humidity-controlled room maintained between 18-22 degree C, and kept to within 1 degree C of change during the examination, is necessary to produce a physiologically neutral image free from artifact.

CORRELATION BETWEEN PATHOLOGY AND INFRARED IMAGING

The empirical evidence that regional skin surface temperatures are altered by underlying breast cancer was investigated early on. In 1963, Lawson and Chughtai, two McGill University surgeons, published an elegant intra-operative study demonstrating that the increase in regional skin surface temperature associated with breast cancer was related to venous convection [4]. This early quantitative experiment added credence to previous research suggesting that infrared findings were related to both increased vascular flow and increased metabolism.

Infrared imaging of the breast may have critical prognostic significance since it may correlate with a variety of pathologic prognostic features such as tumor size, tumor grade, lymph node status and markers of tumor growth [5]. The pathologic basis for these infrared findings, however, is uncertain. One possibility is increased blood flow due to vascular proliferation (assessed by quantifying the microvascular density (MVD)) as a result of tumor associated angiogenesis. Although in one study [6], the MVD did not correlate with abnormal infrared findings. However, the imaging method used in that study consisted of an outdated contact plate technology (liquid crystal thermography (LCT)), which is not capable of modern computerized infrared analysis. Consequently, LCT does not possess the discrimination and digital processing necessary to begin to correlate histological and discrete vascular changes [7].

In 1993, Head and Elliott reported that improved images from second generation infrared systems allowed more objective and quantitative analysis [5], and indicated that growth-rate related prognostic indicators were strongly associated with the infrared image interpretation.

In a 1994 detailed review of the potential of infrared imaging [8], Anbar suggested, using an elegant biochemical and immunological cascade, that the previous empirical observation that small tumors were capable of producing notable infrared changes could be due to enhanced perfusion over a substantial area of the breast surface via regional tumor induced nitric oxide vasodilatation. Nitric oxide is a molecule with potent vasodilating properties. It is synthesized by nitric oxide synthase (NOS), found both as a constitutive form of nitric oxide synthase (c-NOS), especially in endothelial cells, and as an inducible form of nitric oxide synthase (i-NOS), especially in macrophages [9]. NOS has been demonstrated in breast carcinoma [10] using tissue immunohistochemistry, and is associated with a high tumor grade. There have been, however, no previous studies correlating tissue NOS levels with infrared imaging. Given the correlation between infrared imaging and tumor grade, as well as NOS levels and tumor grade, it is possible that infrared findings may correlate with tumor NOS content. Future studies are planned to investigate these possible associations.

The concept of angiogenesis, as an integral part of early breast cancer, was emphasized in 1996 by Guido and Schnitt. Their observations suggested that it is an early event in the development of breast cancer and may occur before tumor cells acquire the ability to invade the surrounding stroma and even before there is morphologic evidence of an in-situ carcinoma [11]. Anti-angiogenesis therapy is now one of the most promising therapeutic strategies and has been found to be pivotal in the new paradigm for consideration of breast cancer development and treatment [12]. In 1996, in his highly reviewed textbook entitled Atlas of Mammography - New Early Signs in Breast Cancer, Gamagami studied angiogenesis by infrared imaging and reported that hypervascularity and hyperthermia could be shown in 86% of non-palpable breast cancers. He also noted that in 15% of these cases infrared imaging helped to detect cancers that were not visible on mammography [13].

The underlying principle by which thermography (infrared imaging) detects pre-cancerous growths and cancerous tumors surrounds the well documented recruitment of existing vascularity and neoangiogenesis in order to maintain the increased metabolism of cellular growth and multiplication. The biomedical engineering evidence of thermography's value, both in model in-vitro and clinically in-vivo studies of various tissue growths, normal and neoplastic, has been established [14-20].

THE ROLE OF INFRARED IMAGING IN THE DETECTION OF CANCER

In order to evaluate the value of thermography, two viewpoints must be considered: first, the sensitivity of thermograms taken preoperatively in patients with known breast carcinoma, and second, the incidence of normal and abnormal thermograms in asymptomatic populations (specificity) and the presence or absence of carcinoma in each of these groups.

In 1965, Gershon-Cohen, a radiologist and researcher from the Albert Einstein Medical Center, introduced infrared imaging to the United States [21]. Using a Barnes thermograph, he reported on 4,000 cases with a sensitivity of 94% and a false-positive rate of 6%. This data was included in a review of the then current status of infrared imaging published in 1968 in CA - A Cancer Journal for Physicians [22].

In prospective studies, Hoffman first reported on thermography in a gynecologic practice. He detected 23 carcinomas in 1,924 patients (a detection rate of 12.5 per 1,000), with an 8.4% false-negative (91.6% sensitivity) and a 7.4% false-

positive (92.6% specificity) rate [23].

Stark and Way screened 4,621 asymptomatic women, 35% of whom were under 35 years of age, and detected 24 cancers (detection rate of 7.6 per 1,000), with a sensitivity and specificity of 98.3% and 93.5% respectively [24].

In a mobile unit examination of rural Wisconsin, Hobbins screened 37,506 women using thermography. He reported the detection of 5.7 cancers per 1,000 women screened with a 12% false-negative and 14% false-positive rate. His findings also corroborated with others that thermography is the sole early initial signal in 10% of breast cancers [25-26].

Reporting his Radiology division's experience with 10,000 thermographic studies done concomitantly with mammography over a 3 year period, Isard reiterated a number of important concepts including the remarkable thermal and vascular stability of the infrared image from year to year in the otherwise healthy patient and the importance of recognizing any significant change [27]. In his experience, combining these modalities increased the sensitivity rate of detection by approximately 10%; thus, underlining the complementarity of these procedures since each one did not always suspect the same lesion. It was Isard's conclusion that, had there been a preliminary selection of his group of 4,393 asymptomatic patients by infrared imaging, mammographic examination would have been restricted to the 1,028 patients with abnormal infrared imaging, or 23% of this cohort. This would have resulted in a cancer detection rate of 24.1 per 1000 combined infrared and mammographic examinations as contrasted to the expected 7 per 1000 by mammographic screening alone. He concluded that since infrared imaging is an innocuous examination, it could be utilized to focus attention upon asymptomatic women who should be examined more intensely. Isard emphasized that, like mammography and other breast imaging techniques, infrared imaging does not diagnose cancer, but merely indicates the presence of an abnormality.

Spitalier and associates screened 61,000 women using thermography over a 10 year period. The false-negative and positive rate was found to be 11% (89% sensitivity and specificity). 91% of the nonpalpable cancers (T0 rating) were detected by thermography. Of all the patients with cancer, thermography alone was the first alarm in 60% of the cases. The authors also noted that "in patients having no clinical or radiographic suspicion of malignancy, a persistently abnormal breast thermogram represents the highest known risk factor for the future development of breast cancer" [28].

Two small-scale studies by Moskowitz (150 patients) [29] and Treatt (515 patients) [30] reported on the sensitivity and reliability of infrared imaging. Both used unknown "experts" to review the images of breast cancer patients. While Moskowitz excluded unreadable images, data from Threatt's study indicated that less than 30% of the images produced were considered good, the rest being substandard. Both of these studies produced poor results; however, this could be expected from the fact alone that both used such a small patient base. However, the greatest error in these studies is found in the methods used to analyze the images. The type of image analysis consisted of the sole use of abnormal vascular pattern recognition. At the time these studies were performed, the most recognized method of infrared image analysis used a combination of abnormal vascular patterns with a quantitative analysis of temperature variations across the breasts. Consequently, the data obtained from these studies is highly questionable. Their findings were also inconsistent with numerous previous large-scale multi-center trials. Both authors suggested that for infrared imaging to be truly effective as a screening tool, there needed to be a more objective means of interpretation and proposed that this would be facilitated by computerized evaluation. However, the use of recognized quantitative and qualitative reading protocols (including computer analysis) was available at the time and would most likely have yielded the results noted in many previous large-scale studies.

In a unique study comprising 39,802 women screened over a 3 year period, Haberman and associates used thermography and physical examination to determine if mammography was recommended. They reported an 85% sensitivity and 70% specificity for thermography. Haberman cautioned that the findings of thermographic specificity could not be extrapolated from this study as it was well documented that long term observation (8-10 years or more) is necessary to determine a true false-positive rate. The authors noted that 30% of the cancers found would not have been detected if it were not for thermography [31].

Gros and Gautherie reported on 85,000 patients screened with a resultant 90% sensitivity and 88% specificity. In order to investigate a method of increasing the sensitivity of the test, 10,834 patients were examined with the addition of a cold-challenge (two types: fan and ice water) in order to elicit an autonomic response. This form of dynamic thermography decreased the false-positive rate to 3.5% (96.5% sensitivity) [32-35].

In a large scale multi-center review of nearly 70,000 women screened, Jones reported a false-negative and false-positive rate of 13% (87% sensitivity) and 15% (85% sensitivity) respectively for thermography [36].

In a study performed in 1986, Usuki reported on the relation of thermographic findings in breast cancer diagnosis. He noted an 88% sensitivity for thermography in the detection of breast cancers [37].

In a study comparing clinical examination, mammography, and thermography in the diagnosis of breast cancer, three groups of patients were used: 4,716 patients with confirmed carcinoma, 3,305 patients with histologically diagnosed benign breast disease, and 8,757 general patients (16,778 total participants). This paper also compared clinical examination and mammography to other well known studies in the literature including the NCI-sponsored Breast Cancer Detection Demonstration Projects. In this study, clinical examination had an average sensitivity of 75% in detecting all tumors and 50% in cancers less than 2 cm in size. This rate is exceptionally good when compared to many other studies at between 35-66% sensitivity. Mammography was found to have an average 80% sensitivity and 73% specificity. Thermography had an average sensitivity of 88% (85% in tumors less than 1 cm in size) and a specificity of 85%. An abnormal thermogram was found to have a 94% predictive value. From the findings in this study, the authors suggested that "none of the techniques available for screening for breast carcinoma and evaluating patients with breast related symptoms is suf-

ficiently accurate to be used alone. For the best results, a multimodal approach should be used" [38].

In a series of 4,000 confirmed breast cancers, Thomassin and associates observed 130 sub-clinical carcinomas ranging in diameter of 3-5 mm. Both mammography and thermography were used alone and in combination. Of the 130 cancers, 10% were detected by mammography only, 50% by thermography alone, and 40% by both techniques. Thus, there was a thermal alarm in 90% of the patients and the only sign in 50% of the cases [39].

In a study by Gautherie and associates, the effectiveness of thermography in terms of survival benefit was discussed. The authors analyzed the survival rates of 106 patients in whom the diagnosis of breast cancer was established as a result of the follow-up of thermographic abnormalities found on the initial examination when the breasts were apparently healthy (negative physical and mammographic findings). The control group consisted of 372 breast cancer patients. The patients in both groups were subjected to identical treatment and followed for 5 years. A 61% increase in survival was noted in the patients who were followed-up due to initial thermographic abnormalities. The authors summarized the study by stating that "the findings clearly establish that the early identification of women at high risk of breast cancer based on the objective thermal assessment of breast health results in a dramatic survival benefit" [40-41].

In a simple review of over 15 studies from 1967 - 1998, breast thermography has showed an average sensitivity and specificity of 90%. With continued technological advances in infrared imaging in the past decade, some studies are showing even higher sensitivity and specificity values. However, until further large scale studies are performed, these findings remain in question.

BREAST CANCER DETECTION AND DEMONSTRATION PROJECTS

The Breast Cancer Detection and Demonstration Project (BCDDP) is the most frequently quoted reason for the decreased use of infrared imaging. The BCDDP was a large-scale study performed from 1973 through 1979 which collected data from many centers around the United States. Three methods of breast cancer detection were studied: physical examination, mammography, and infrared imaging (breast thermography).

Inflated Expectations -- Just before the onset of the BCDDP, two important papers appeared in the literature. In 1972, Gerald D. Dodd of the University of Texas Department of Diagnostic Radiology presented an update on infrared imaging in breast cancer diagnosis at the 7th National Cancer Conference sponsored by the National Cancer Society and the National Cancer Institute [42]. In his presentation, he suggested that infrared imaging would be best employed as a screening agent for mammography. He proposed that in any general survey of the female population age 40 and over, 15 to 20% of these subjects would have positive infrared imaging and would require mammograms. Of these, approximately 5% would be recommended for biopsy. He concluded that infrared imaging would serve to eliminate 80 to 85% of the potential mammograms. Dodd also reiterated that the procedure was not competitive with mammography and, reporting the Texas Medical School's experience with infrared imaging, noted that it was capable of detecting approximately 85% of all breast cancers. Dodd's ideas would later help to fuel the premise and attitudes incorporated into the BCDDP. Three years later, J.D. Wallace presented to another Cancer Conference, sponsored by the American College of Radiology, the American Cancer Society and the Cancer Control Program of the National Cancer Institute, an update on infrared imaging of the breast [43]. The author's analysis suggested that the incidence of breast cancer detection per 1000 patients screened could increase from 2.72 when using mammography to 19 when using infrared imaging. He then underlined that infrared imaging poses no radiation burden on the patient, requires no physical contact and, being an innocuous technique, could concentrate the sought population by a significant factor selecting those patients that required further investigation. He concluded that, "the resulting infrared image contains only a small amount of information as compared to the mammogram, so that the reading of the infrared image is a substantially simpler task".

Faulty Premise -- Unfortunately, this rather simplistic and cavalier attitude toward the generation and interpretation of infrared imaging was prevalent when it was hastily added and then prematurely dismissed from the BCDDP which was just getting underway. Exaggerated expectations led to the ill-founded premise that infrared imaging might replace mammography rather than complement it. A detailed review of the Report of the Working Group of the BCDDP, published in 1979, is essential to understand the subsequent evolution of infrared imaging [44]. The work scope of this project was issued by the NCI on the 26th of March 1973 with six objectives, the second being to determine if a negative infrared image was sufficient to preclude the use of clinical examination and mammography in the detection of breast cancer. The Working Group, reporting on results of the first four years of this project, gave a short history regarding infrared imaging in breast cancer detection. They wrote that as of the sixties, there was intense interest in determining the suitability of infrared imaging for large-scale applications, and mass screening was one possibility. The need for technological improvement was recognized and the authors stated that efforts had been made to refine the technique. One of the important objectives behind these efforts had been to achieve a sufficiently high sensitivity and specificity for infrared imaging under screening conditions to make it useful as a pre-screening device in selecting patients for referral for mammographic examination. It was thought that if successful, this technology would result in a relatively small proportion of women having mammography (a technique that had caused concern at that time because of the carcinogenic effects of radiation). The Working Group indicated that the sensitivity and specificity of infrared imaging readings, with clinical data emanating from inter-institutional studies, were close to the corresponding results for physical examination and mammography. They noted that these three modalities selected different sub-groups of breast cancers, and for this reason further evaluation of infrared imaging as a screening device in a controlled clinical trial was recommended.

Poor Study Design -- While this report describes in detail the importance of quality control of mammography, the entire

protocol for infrared imaging was summarized in one paragraph and simply indicated that infrared imaging was conducted by a BCDDP trained technician. The detailed extensive results from this report, consisting of over 50 tables, included only one that referred to infrared imaging showing that it had detected only 41% of the breast cancers during the first screening while the residual were either normal or unknown. There is no breakdown as far as these two latter groups were concerned. Since 28% of the first screening and 32% of the second screening were picked up by mammography alone, infrared imaging was dropped from any further evaluation and consideration. The report stated that it was impossible to determine whether abnormal infrared imaging could be predictive of interval cancers (cancers developing between screenings) since they did not collect this data. By the same token, the Working Group was unable to conclude, with their limited experience, whether the findings were related to the then available technology of infrared imaging or with its application. They did, however, conclude that the decision to dismiss infrared imaging should not be taken as a determination of the future of this technique, rather that the procedure continued to be of interest because it does not entail the risk of radiation exposure. In the Working Group's final recommendation, they state that "infrared imaging does not appear to be suitable as a substitute for mammography for routine screening in the BCDDP." The report admitted that several individual programs of the BCDDP had results that were more favorable than what was reported for the BCDDP as a whole. They encouraged investment in the development and testing of infrared imaging under carefully controlled study conditions and suggested that high priority be given to these studies. They noted that a few suitable sites appeared to be available within the BCDDP participants and proposed that developmental studies should be solicited from sites with sufficient experience.

Untrained Personnel and Protocol Violations -- JoAnn Haberman, who was a participant in this project [45], provided further insight into the relatively simplistic regard assigned to infrared imaging during this program. The author reiterated that expertise in mammography was an absolute requirement for the awarding of a contract to establish a Screening Center. However, the situation was just the opposite with regard to infrared imaging – no experience was required at all. When the 27 demonstration project centers opened their doors, only 5 had any pre-existing expertise in infrared imaging. Of the remaining screening centers, there was no experience at all in this technology. Finally, more than 18 months after the project had begun, the NCI established centers where radiologists and their technicians could obtain sufficient training in infrared imaging. Unfortunately, only 11 of the demonstration project directors considered this training of sufficient importance to send their technologists to learn proper infrared technique. Environmental controls were also disregarded by the imaging sites. Many of the project sites were mobile imaging vans which had poor heating and cooling capabilities and often kept their doors open in the front and rear to permit an easy flow of patients. This, combined with a lack of pre-imaging patient acclimation, lead to unreadable images.

In summary, with regard to thermography, the BCDDP was plagued with problems and seriously flawed in four critical areas: (1) Completely untrained technicians were used to perform the scans, (2) The study used radiologists who had no experience or knowledge in reading infrared images, (3) Proper laboratory environmental controls were completely ignored. In fact, many of the research sites were mobile trailers with extreme variations in internal temperatures, (4) No standardized reading protocol had yet been established for infrared imaging. The BCDDP was also initiated with an incorrect premise that thermography might replace mammography. From a purely scientific point, an anatomical imaging procedure (mammography) cannot be replaced by a physiological one. Last of all, and of considerable concern, was the reading of the images. It wasn't until the early 1980's that established and standardized reading protocols were introduced. Considering these facts, the BCDDP could not have properly evaluated infrared imaging. With the advent of known laboratory environmental controls, established reading protocols, and state-of-the-art infrared technology, a poorly performed 20-year-old study cannot be used to determine the appropriateness of thermography.

THERMOGRAPHY AS A RISK INDICATOR

As early as 1976, at the Third International Symposium on Detection and Prevention of Cancer in New York, thermography was established by consensus as the highest risk marker for the possibility of the presence of an undetected breast cancer. It had also been shown to predict such a subsequent occurrence [46-48]. The Wisconsin Breast Cancer Detection Foundation presented a summary of its findings in this area, which has remained undisputed [49]. This, combined with other reports, has confirmed that thermography is the highest risk indicator for the future development of breast cancer and is 10 times as significant as a first order family history of the disease [50].

In a study of 10,000 women screened, Gautherie found that, when applied to asymptomatic women, thermography was very useful in assessing the risk of cancer by dividing patients into low- and high-risk categories. This was based on an objective evaluation of each patient's thermograms using an improved reading protocol that incorporated 20 thermopathological factors [51].

From a patient base of 58,000 women screened with thermography, Gros and associates followed 1,527 patients with initially healthy breasts and abnormal thermograms for 12 years. Of this group, 40% developed malignancies within 5 years. The study concluded that "an abnormal thermogram is the single most important marker of high risk for the future development of breast cancer" [35].

Spitalier and associates followed 1,416 patients with isolated abnormal breast thermograms. It was found that a persistently abnormal thermogram, as an isolated phenomenon, is associated with an actuarial breast cancer risk of 26% at 5 years. Within this study, 165 patients with non-palpable cancers were observed. In 53% of these patients, thermography was the only test which was positive at the time of initial evaluation. It was concluded that: (1) A persistently abnormal

thermogram, even in the absence of any other sign of malignancy, is associated with a high risk of developing cancer, (2) This isolated abnormal also carries with it a high risk of developing interval cancer, and as such the patient should be examined more frequently than the customary 12 months, (3) Most patients diagnosed as having minimal breast cancer have abnormal thermograms as the first warning sign [52-53].

CURRENT STATUS OF DETECTION

Current first-line breast cancer detection strategy still depends essentially on clinical examination and mammography. The limitations of the former, with its reported sensitivity rate often below 65% [54] is well-recognized, and even the proposed value of self-breast examination is now being contested [55]. While mammography is accepted as the most reliable and cost-effective imaging modality, its contribution continues to be challenged with persistent false-negative rates ranging up to 30% [56-57]; with decreasing sensitivity in patients on estrogen replacement therapy [58]. In addition, there is recent data suggesting that denser and less informative mammography images are precisely those associated with an increased cancer risk [59]. Echoing some of the shortcomings of the BCDDP concerning their study design and infrared imaging, Moskowitz indicated that mammography is also not a procedure to be performed by the untutored [60].

With the current emphasis on earlier detection, there is now renewed interest in the parallel development of complimentary imaging techniques that can also exploit the precocious metabolic, immunological and vascular changes associated with early tumor growth. While promising, techniques such as scintimammography [61], doppler ultrasound [62], and MRI [63], are associated with a number of disadvantages that include exam duration, limited accessibility, need of intravenous access, patient discomfort, restricted imaging area, difficult interpretation and limited availability of the technology. Like ultrasound, they are more suited to use as second-line options to pursue the already abnormal clinical or mammographic evaluation. While practical, this step-wise approach currently results in the non-recognition, and thus delayed utilization of second-line technology in approximately 10% of established breast cancers [60]. This is consistent with a recently published study by Keyserlingk et al [64].

Because of thermography's unique ability to image the thermovascular aspects of the breast, extremely early warning signals (from 8-10 years before any other detection method) have been observed in long-term studies. Consequently, thermography is the earliest known indicator for the future development of breast cancer. It is for this reason that an abnormal infrared image is the single most important marker of high risk for developing breast cancer. Thus, thermography has a significant place as one of the major front-line methods of breast cancer detection.

CONCLUSION

The large patient populations and long survey periods in many of the above clinical studies yields a high significance to the various statistical data obtained. This is especially true for the contribution of thermography to early cancer diagnosis, as an invaluable marker of high-risk populations, and therapeutic decision making, a contribution that has been established and justified by the unequivocal relationship between heat production and tumor doubling time.

Currently available high-resolution digital infrared imaging (Breast Thermography) technology benefits greatly from enhanced image production, standardized image interpretation protocols, computerized comparison and storage, and sophisticated image enhancement and analysis. Over 30 years of research and 800 peer-reviewed studies encompassing well over 300,000 women participants has demonstrated infrared imaging's abilities in the early detection of breast cancer. Ongoing research into the thermal characteristics of breast pathologies will continue to investigate the relationships between neoangiogenesis, chemical mediators, and the neoplastic process.

It is unfortunate, but many physicians still hesitate to consider thermography as a useful tool in clinical practice in spite of the considerable research database, continued improvements in both thermographic technology and image analysis, and continued efforts on the part of the thermographic societies. This attitude may be due to the fact that the physical and biological bases of thermography are not familiar to most physicians. The other methods of cancer investigations refer directly to topics of medical teaching. For instance, radiography and ultrasonography refer to anatomy. Thermography, however, is based on thermodynamics and thermokinetics, which are unfamiliar to most physicians, though man is experiencing heat production and exchange in every situation he undergoes or creates.

Considering the contribution that thermography has demonstrated thus far in the field of early cancer detection, all possibilities should be considered for promoting further technical, biological, and clinical research in this procedure.

REFERENCES

- [1] Adams, F.: *The Genuine Works of Hippocrates*. Baltimore: Williams and Wilkins, 1939.
- [2] Lawson R.: *Implications of Surface Temperatures in the Diagnosis of Breast Cancer*. Can Med Assoc J 75: 309-310, 1956.
- [3] Archer, F., Gros, C.: *Classification Thermographique des Cancers Mammaires*. Bull Cancer 58:351-362, 1971
- [4] Lawson RN and Chughtai MS: *Breast cancer and body temperatures*. Can Med Assoc J 88: 68-70, 1963.
- [5] Head JF, Wang F, Elliott RL: *Breast thermography is a noninvasive prognostic procedure that predicts tumor growth rate in breast cancer patients*. Ann N Y Acad Sci 698:153-158, 1993.
- [6] Sterns EE, Zee B, Sen Gupta J, and Saunders FW. *Thermography: Its relation to pathologic characteristics, vascularity, proliferative rate and survival of patients with invasive ductal carcinoma of the breast*. Cancer 77:1324-8, 1996.

- [7] Head JF, Elliott RL: *Breast Thermography*. Cancer 79:186-8,1995.
- [8] Anbar M: *Breast Cancer*. In: Quantitative Dynamic Telethermometry in Medical Diagnosis and Management. CRC Press, Ann Arbor, Mich, pp.84-94, 1994.
- [9] Rodenberg DA, Chaet MS, Bass RC, Arkovitz MD and Garcia BF. *Nitric Oxide: An overview*. Am J Surg 170:292-303,1995.
- [10] Thomsen LL, Miles DW, Happerfield L, Bobrow LG, Knowles RG and Mancada S. *Nitric oxide synthase activity in human breast cancer*. Br J Cancer 72(1);41-4, July 1995.
- [11] Guidi AJ, Schnitt SJ: *Angiogenesis in pre-invasive lesions of the breast*. The Breast J (2): 364-369, 1996.
- [12] Love SM, Barsky SH: *Breast Cancer: An interactive Paradigm*. Breast J 3: 171-5,1996.
- [13] Gamagami P: *Indirect signs of breast cancer: Angiogenesis study*. In: Atlas of Mammography, Cambridge, Mass., Blackwell Science pp.231-26, 1996.
- [14] Love, T.: *Thermography as an Indicator of Blood Perfusion*. Proc NY Acad Sci J 335:429-437,1980.
- [15] Chato, J.: *Measurement of Thermal Properties of Growing Tumors*. Proc NY Acad Sci 335:67-85,1980.
- [16] Draper, J. : *Skin Temperature Distribution Over Veins and Tumors*. Phys Med Biol 16(4):645-654,1971
- [17] Jain, R.; Gullino, P.: *Thermal Characteristics of Tumors: Applications in Detection and Treatment*. Ann NY Acad Sci 335:1-21,1980
- [18] Gautherie, M.: *Thermopathology of Breast Cancer; Measurement and Analysis of In-Vivo Temperature and Blood Flow*. Ann NY Acad Sci 365:383, 1980
- [19] Gautherie, M.: *Thermobiological Assessment of Benign and Malignant Breast Diseases*. Am J Obstet Gynecol (8) 147:861-869, 1983
- [20] Gamigami, P.: *Atlas of Mammography: New Early Signs in Breast Cancer*. Blackwell Science, 1996.
- [21] Gershen-Cohen J, Haberman J, Brueschke EE: *Medical thermography: A summary of current status*. Radiol Clin North Am 3:403-431, 1965.
- [22] Haberman J: *The present status of mammary thermography*. In: Ca - A Cancer Journal for Clinicians 18: 314-321,1968.
- [23] Hoffman, R.: *Thermography in the Detection of Breast Malignancy*. Am J Obstet Gynecol 98:681-686, 1967
- [24] Stark, A., Way, S.: *The Screening of Well Women for the Early Detection of Breast Cancer Using Clinical Examination with Thermography and Mammography*. Cancer 33:1671-1679, 1974
- [25] Hobbins, W.: *Mass Breast Cancer Screening*. Proceedings, Third International Symposium on Detection and Prevention of Breast Cancer, New York City, NY: pg. 637, 1976.
- [26] Hobbins, W.: *Abnormal Thermogram -- Significance in Breast Cancer*. RIR 12: 337-343, 1987
- [27] Isard HJ, Becker W, Shilo R et al: *Breast thermography after four years and 10,000 studies*. Am J Roentgenol 115: 811-821,1972.
- [28] Spitalier, H., Giraud, D., et al: *Does Infrared Thermography Truly Have a Role in Present-Day Breast Cancer Management?* Biomedical Thermology, Alan R. Liss New York, NY. pp. 269-278, 1982
- [29] Moskowitz M, Milbrath J, Gartside P et al: *Lack of efficacy of thermography as a screening tool for minimal and Stage I Breast Cancer*. N Engl J Med 295; 249-252,1976.
- [30] Threatt B, Norbeck JM, Ullman NS, et al: *Thermography and breast cancer: an analysis of a blind reading*. Annals N Y Acad Sci 335: 501-519,1980.
- [31] Haberman, J., Francis, J., Love, T.: *Screening a Rural Population for Breast Cancer Using Thermography and Physical Examination Techniques*. Ann NY Acad Sci 335:492-500,1980
- [32] Sciarra, J.: *Breast Cancer: Strategies for Early Detection*. Thermal Assessment of Breast Health. (Proceedings of the International Conference on Thermal Assessment of Breast Health). MTP Press LTD. pp. 117-129, 1983.